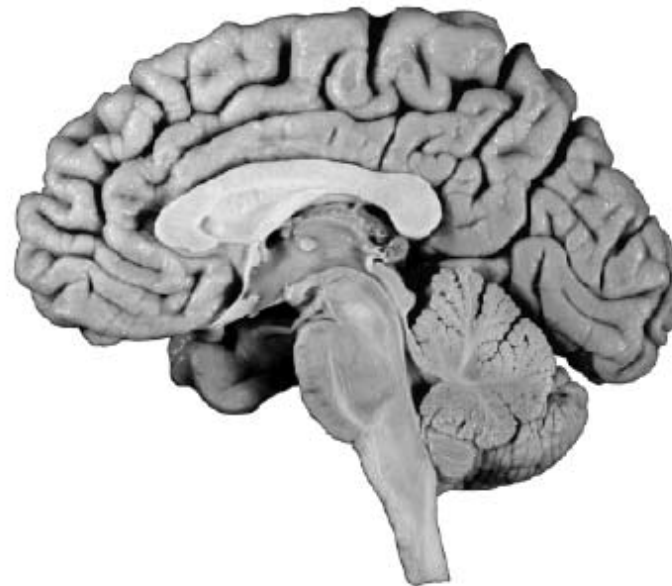
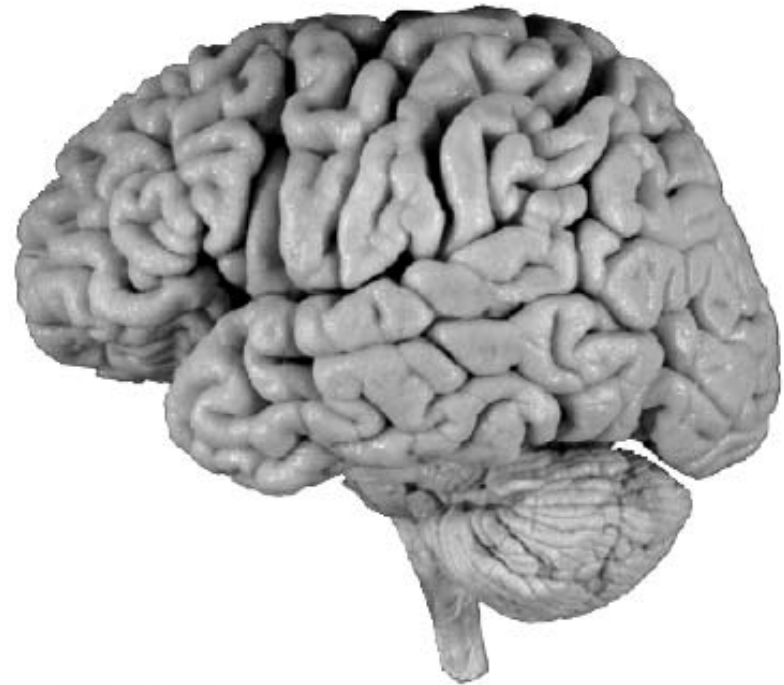
Cerebral Cortex

- Brain's most complex area with billions of neurons and trillions of synapses: the tissue responsible for mental activities: consciousness, perceives sensations, skilled movements, emotional awareness, memory, thinking, language ability, motivation

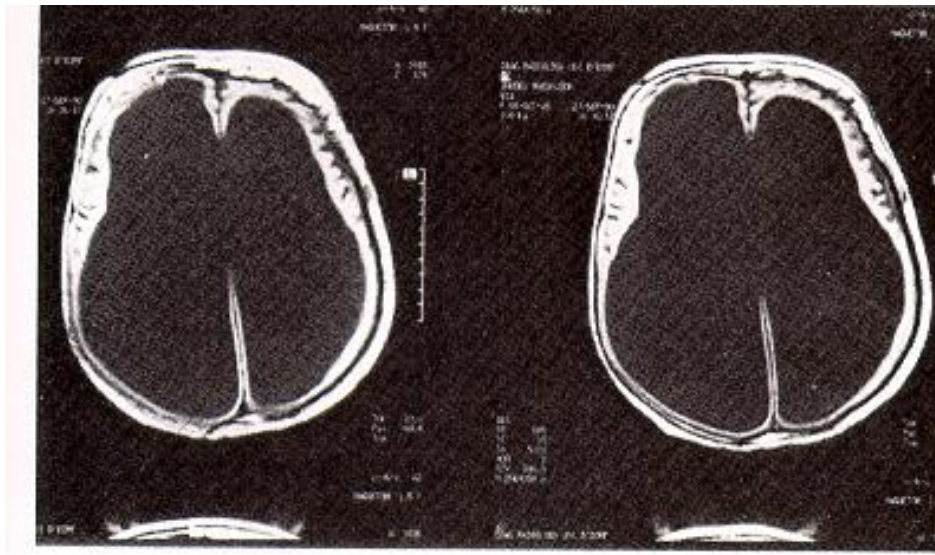


Is Your Brain Really Necessary?

John Lorber, Science 210:1232 (1980)

"There a young student at this university who has an IQ of 126, has gained a first-class honors degree in mathematics, and is socially completely normal. And yet the boy has virtually no brain."

"The student's physician at the university noticed that the student had slightly larger than normal head... When we did a brain scan on him we saw that instead of the normal 4.5 cm thickness of brain tissue there was just a millimeter or so. His cranium is filled with CSF."



How is this possible?

What does it tell us?

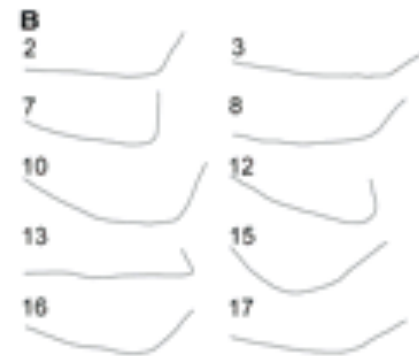
Do you think this would be OK if it happened to an adult? To a 15 year old? To a 5 year old? To a neonate?

Types of Cerebral Cortex

- **Neocortex**
 - Newest in evolution
 - About 90% of total
 - 6 layers, most complex
- **Paleocortex**
 - Associated with olfactory system, the parahippocampal gyrus, uncus
 - fewer than 6 layers
- **Archicortex**
 - Hippocampal formation; limbic system
 - 3 layers, most primitive
- **Mesocortex**
 - Cingulate gyrus, insular cortex
 - Transitional between archicortex and neocortex

The perks of having a neocortex

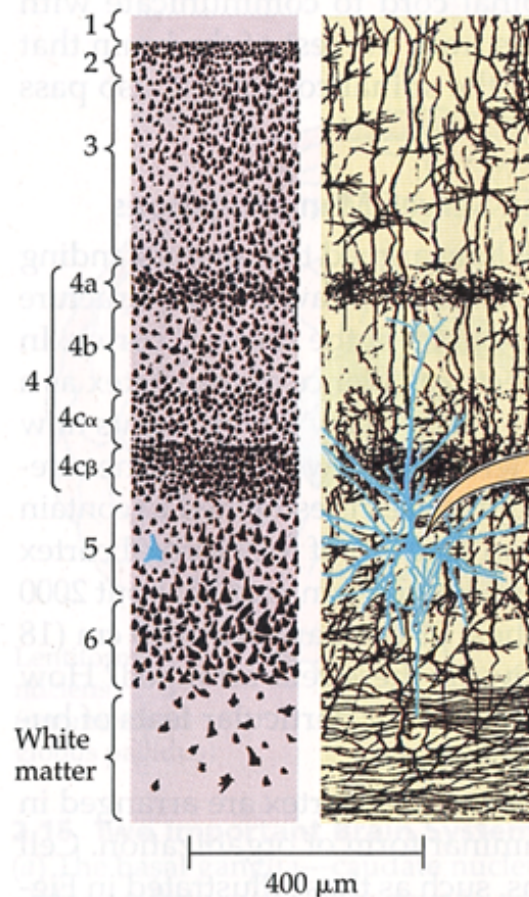
- The words used to describe the higher mental capacities of animals with a large neocortex include:
 - **CONSCIOUSNESS**
 - **FREE WILL**
 - **INTELLIGENCE**
 - **INSIGHT**
- Animals with much simpler brains learn well, so **LEARNING** should not be among these capacities (Macphail 1982).
- A species could have genetically determined mechanisms, acquired through evolutionary selection, for taking advantage of the **regular features of the environment**, or they could have learned through **direct experience**.



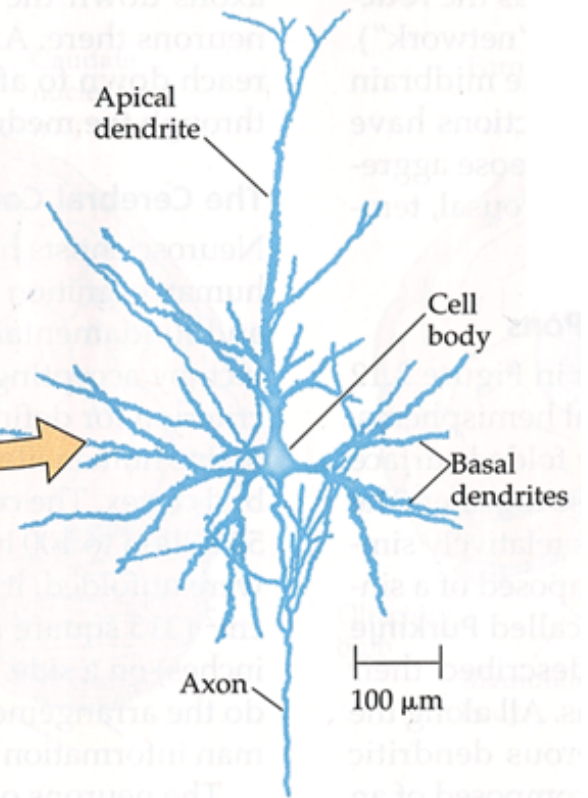
Histology of the Cerebral Cortex

- Neocortex has 6 layers designated I, II, III, IV, V, VI
- Pyramidal cells predominate in layers III and V
- Granule cells in layers II and IV

(a) Six layers of cortex

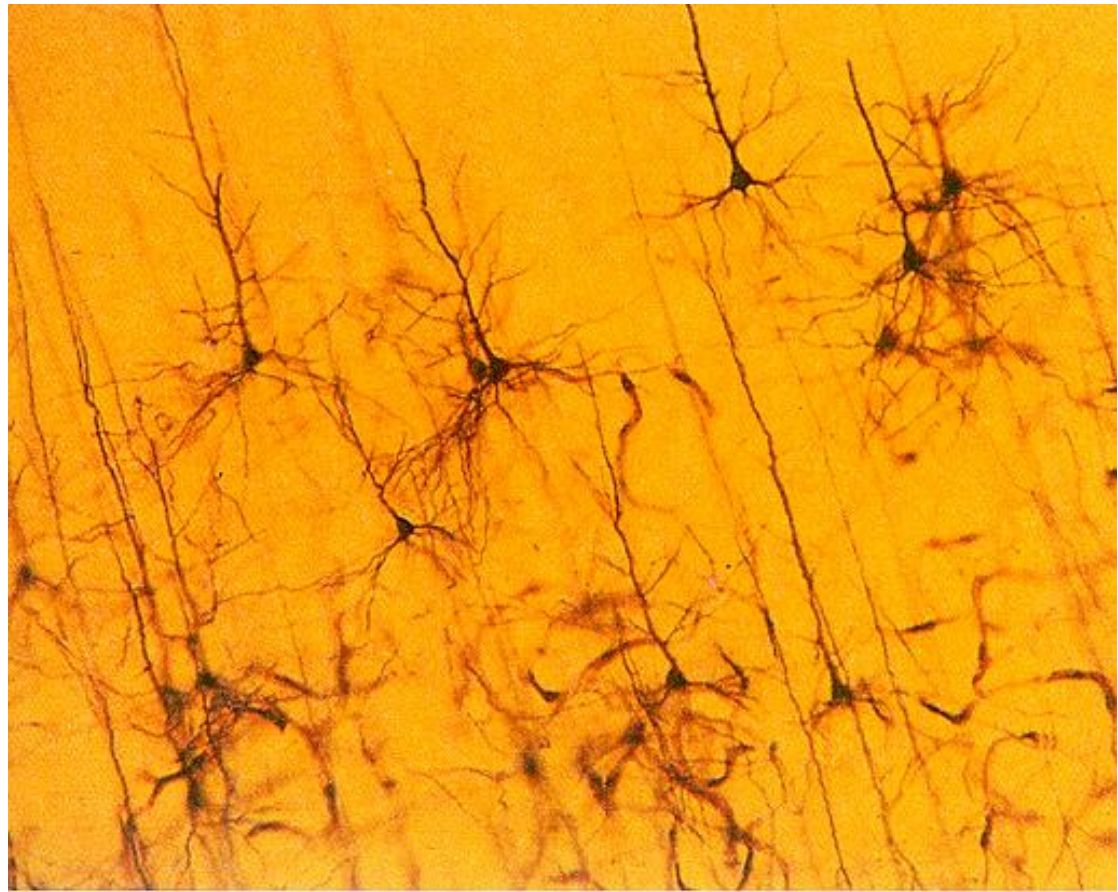


(b) A single pyramidal neuron




Pyramidal neurons

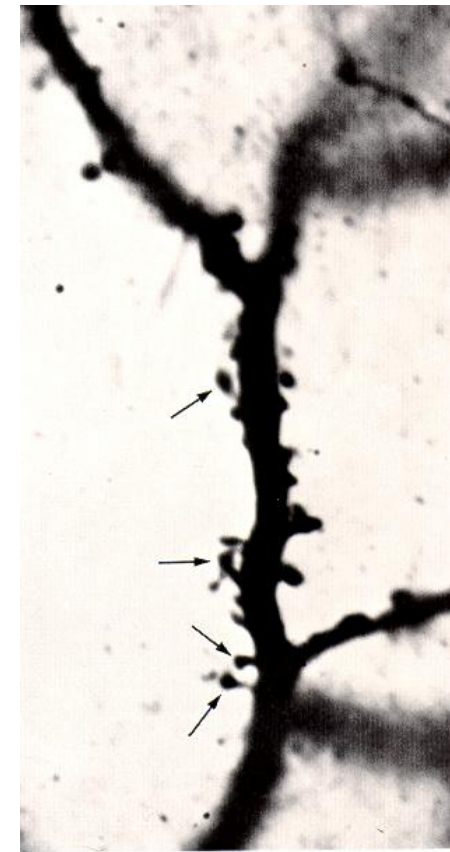
- Have large apical dendrite and basal dendrites
- Similar orientation
- Process input from many sources
- Axon projects downward into subcortical white matter
- Pyramidal cell is the primary output cortical neuron (Betz cells)



Dendritic Spines



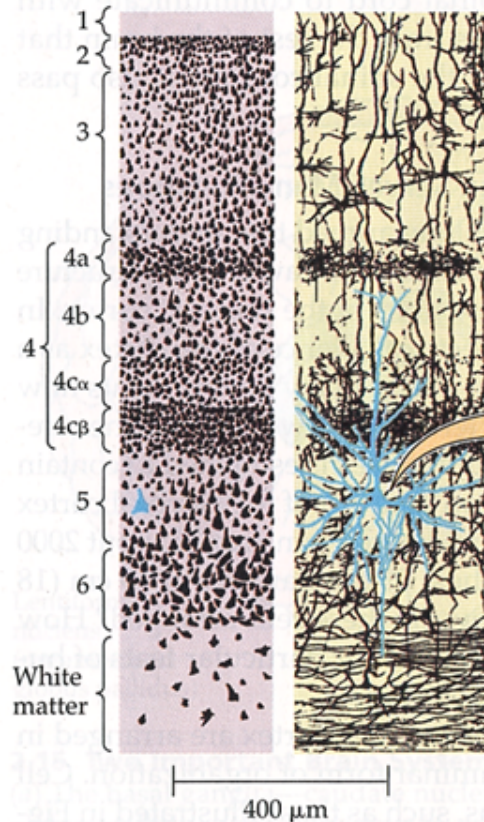
- Spines become more complex in early years
- Spine abnormalities occur in some conditions where mental performance is diminished



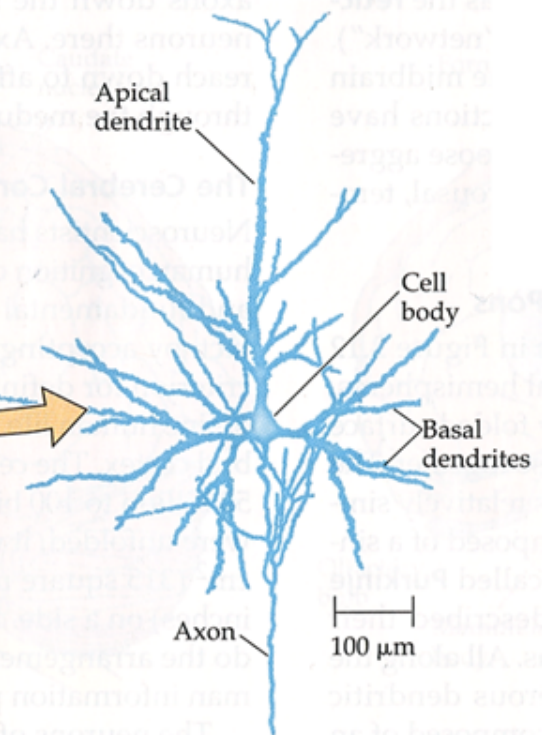
Layers of neocortex

- 1. Molecular layer**
 - Horizontal connections
- 2. External granular layer**
 - Small granule cells, intracortical connections
- 3. External pyramidal layer**
 - Smaller pyramids, callosal and intracortical outputs
- 4. Internal granular layer**
 - Larger granular cells, inputs from primary sensory thalamic nuclei
- 5. Internal pyramidal layer**
 - Larger pyramids, main output to subcortex
- 6. Fusiform or multiform layer**
 - Mixture of cell types, main output to thalamus

(a) Six layers of cortex



(b) A single pyramidal neuron



© 1998 Sinauer Associat

Types of Cortex

- Cytoarchitecture varies in different areas
- Number and size of cells
- Thickness of layers

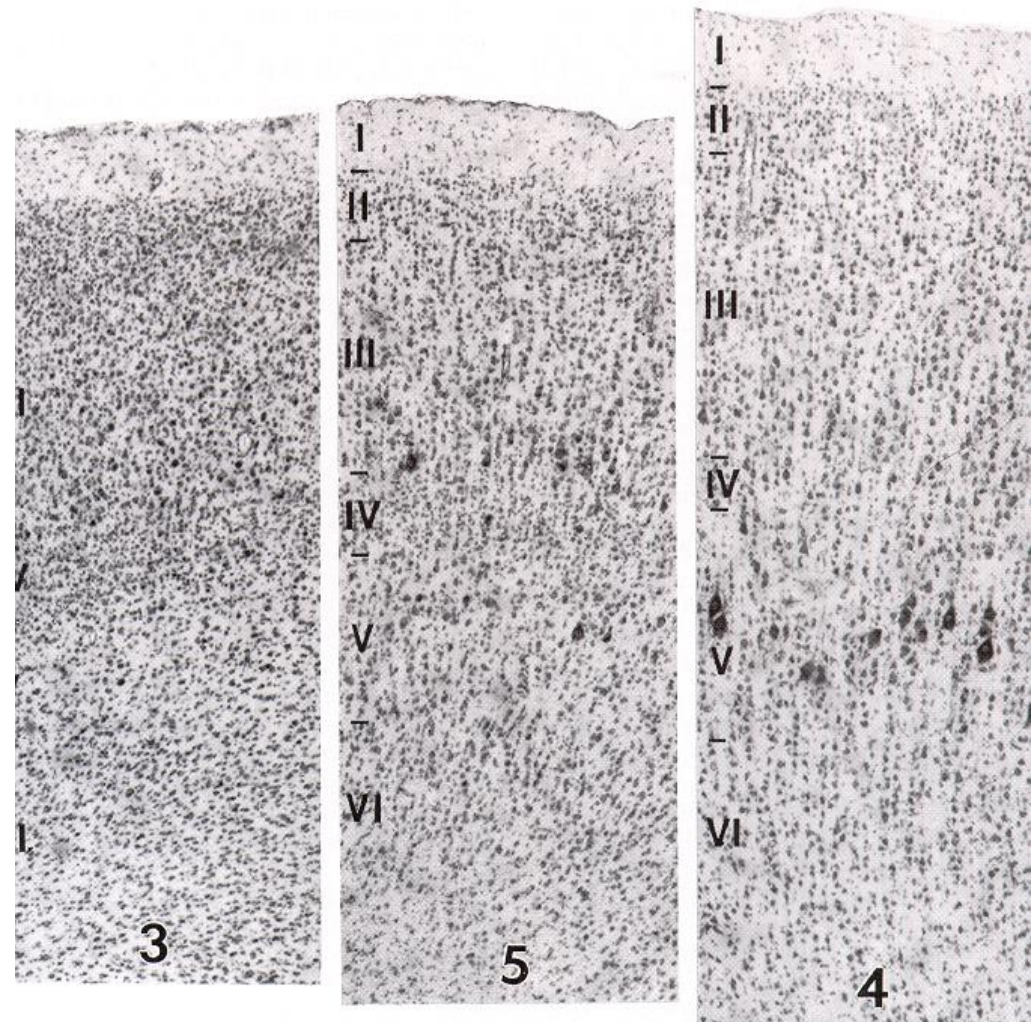
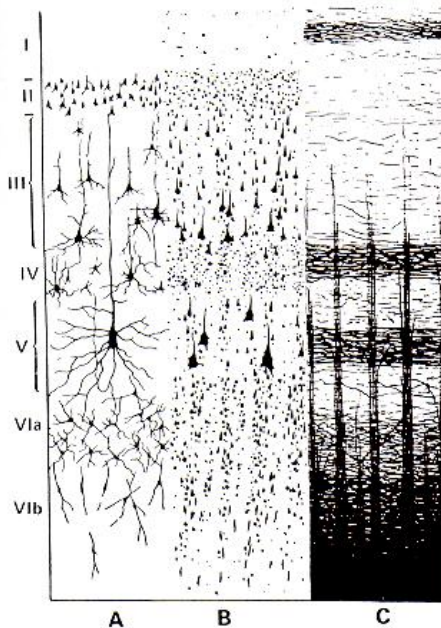
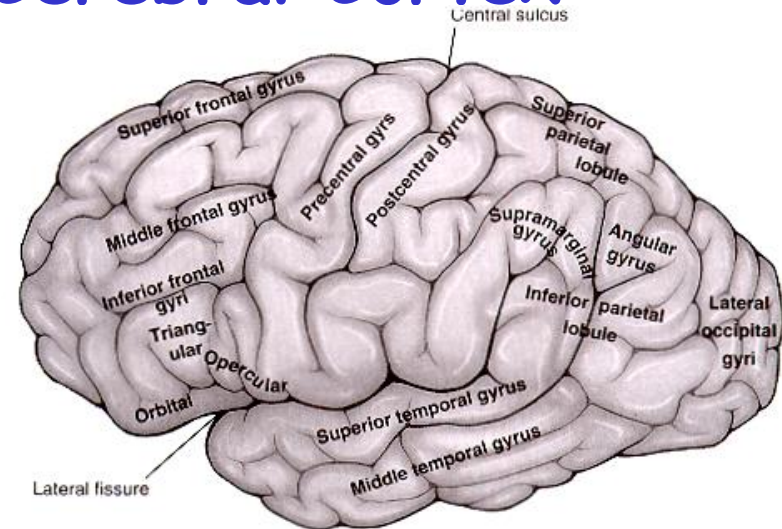


Figure 17-5

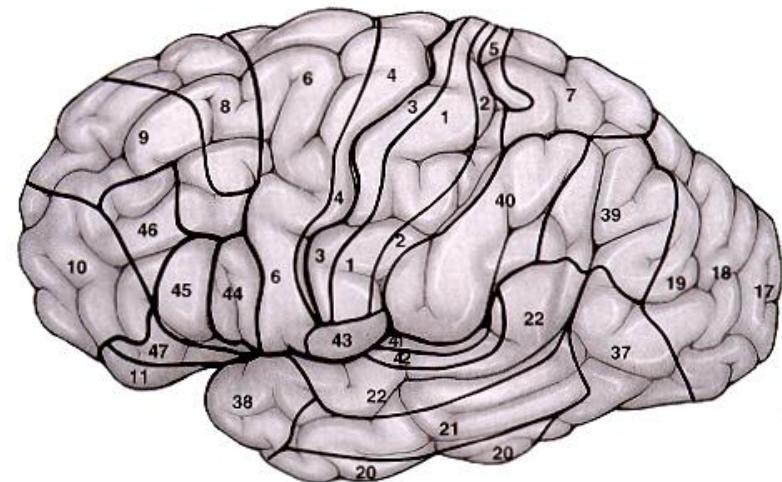
Photomicrographs of Nissl-stained sections through three sensorimotor areas to show differences in cytoarchitectural organization: primary somatosensory cortex (*area 3*); first somatosensory association cortex (*area 5*); motor cortex (*area 4*). Notice the highly granular layers II and IV in area 3 and large pyramidal neurons in the deep part of layer III in area 5 and in layer V of area 4.

Functional Areas of Cerebral Cortex

- Anatomically the cortex is divided into 6 lobes: frontal, parietal, temporal, occipital, limbic and insular
- Each lobe has several gyri
- Functionally the cortex is divided into numbered areas first proposed by **Brodmann in 1909**
- Brodmann's areas were described based on cytoarchitecture; later they were found to be functionally significant



A. Principal gyri and sulci

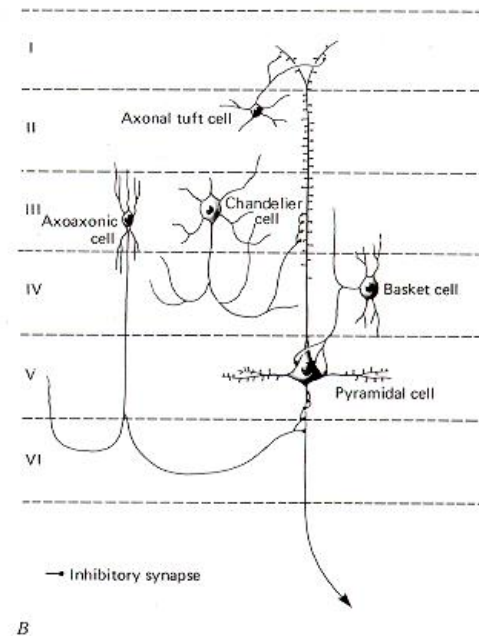
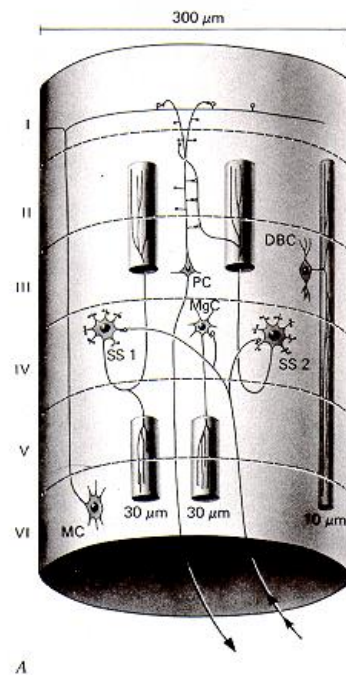


B. Brodmann areas

FIGURE 15-6. Lateral views of left hemisphere. A. Gyri and sulci. B. Brodmann areas.

Cortical Columns

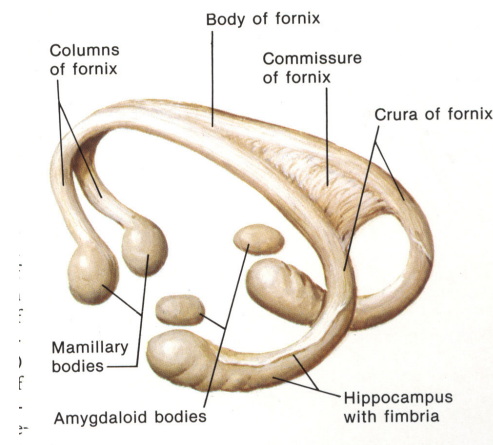
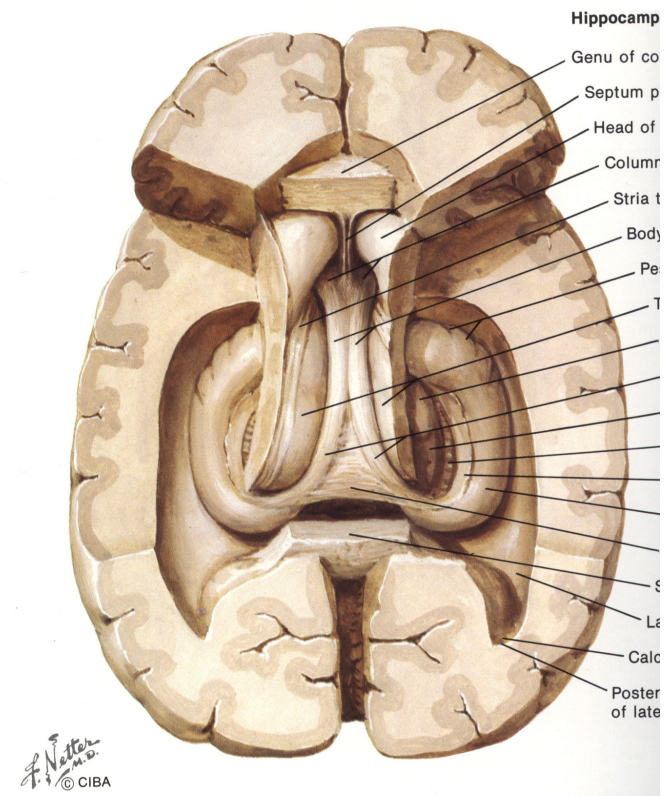
- Run vertically across all six layers
- Thousands of neurons in synaptic contact
- Main input layer is layer IV which receives thalamic input
- Are the basic units of the peripheral representation in the sensory cortex (e.g. retinotopy or tonotopy)
- Within a column neurons have similar response properties (e.g. characteristic frequency in the auditory cortex).



How do cortical columns relate to the radial organization of cortical development?

Cortical Connections

- Intracortical fibers
- Association fibers
- Commissural fibers
- Projection fibers



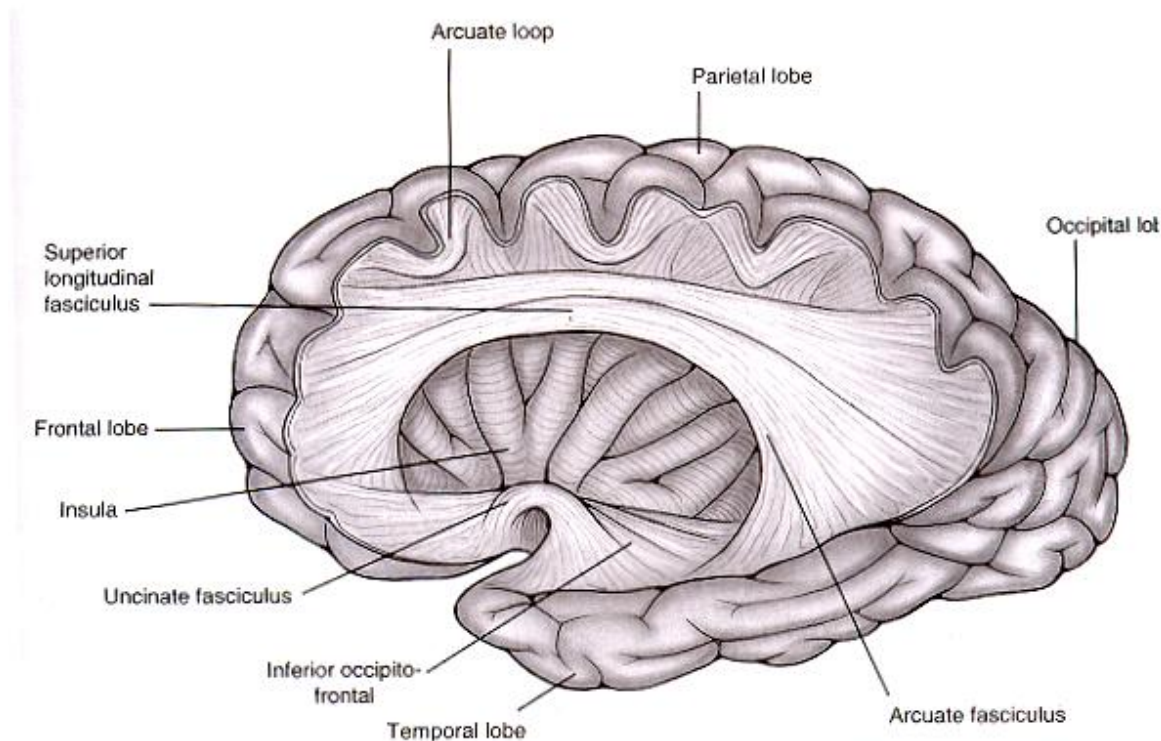
Cortical Connections

- **Intracortical fibers**
 - short, project to nearby cortical areas
 - most from horizontal neurons in layer I
 - some from horizontal axon collaterals from pyramidal cells

Cortical Connections

- **Association fibers**

- gyrus to gyrus and lobe to lobe in the same hemisphere
- arcuate fibers connect adjacent gyri
- long association fibers connect distant gyri
- originate from pyramidal neurons in layers II and III



Cortical Connections

- Commissural fibers

- connect homologous areas of the two hemispheres
- Corpus callosum: rostrum, genu, trunk, splenium
 - rostrum & genu connect frontal lobes
 - trunk connects posterior frontal lobes, parietal lobes, and superior temporal lobe
 - splenium connects the occipital lobes
- Originate with pyramidal neurons in layers II and III

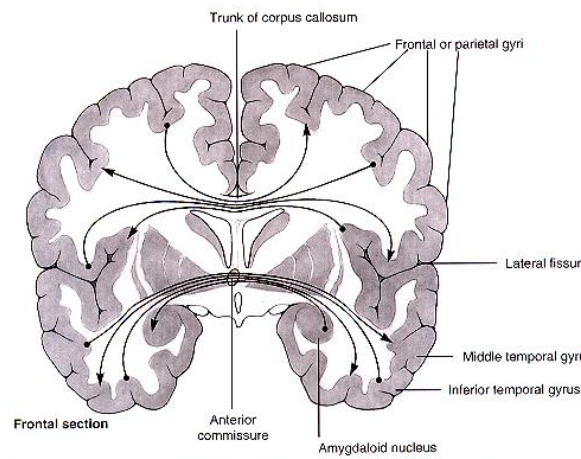


FIGURE 15-4B. Connections of anterior commissure and trunk of corpus callosum.

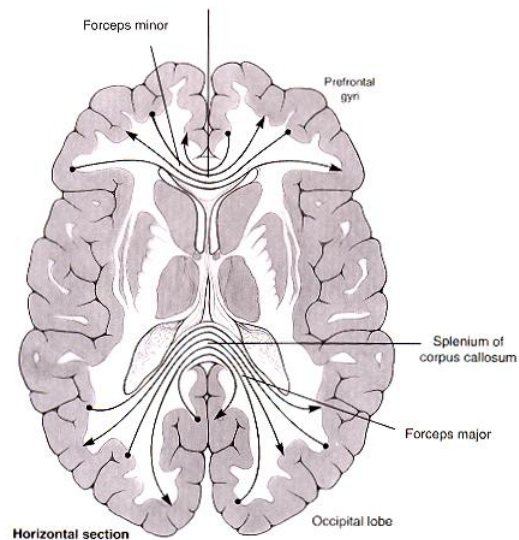
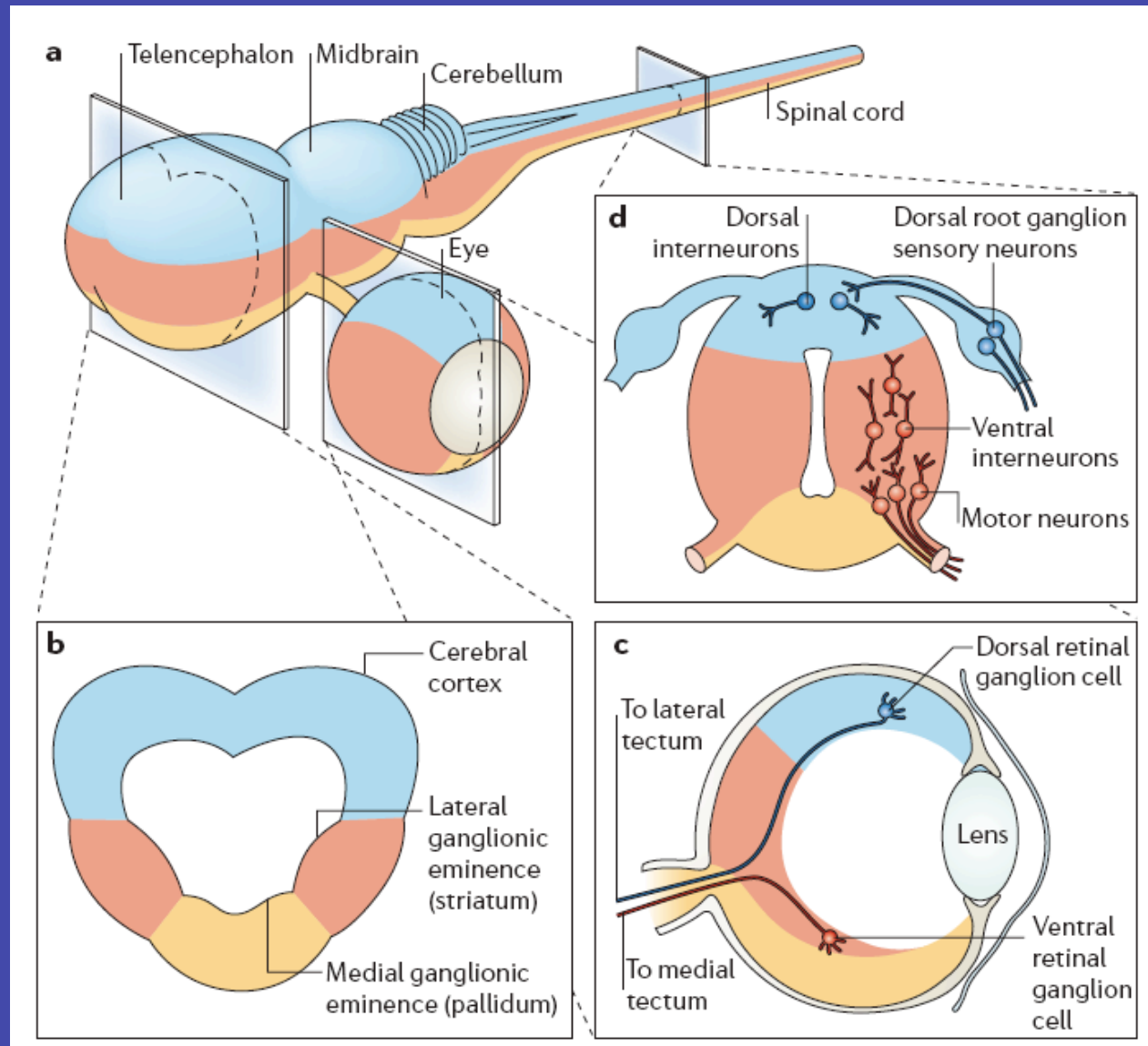


FIGURE 15-4A. Connections of genu and splenium of corpus callosum: Forceps minor and maj

Cortical Connections

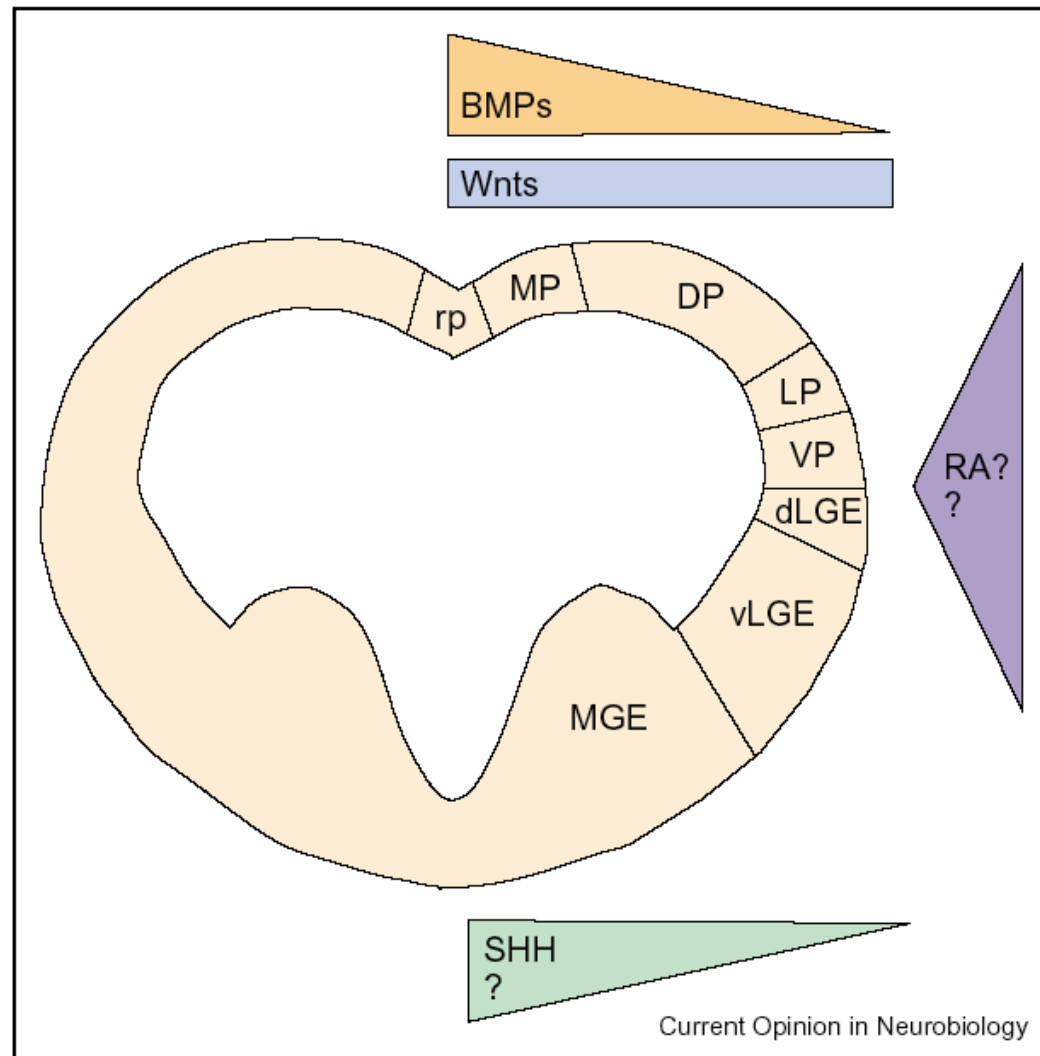
- **Projection fibers** connect cortex with subcortical neurons
 - corticofugal/efferent, project from cortex
 - corticopetal/afferent, project to cortex
- **Corticofugal** project to corpus striatum, brainstem, and spinal cord
- **Corticopetal** projections arise mainly from the thalamus - the thalamic radiations
- **Internal capsule** carries most of these connections

DV patterning in the CNS

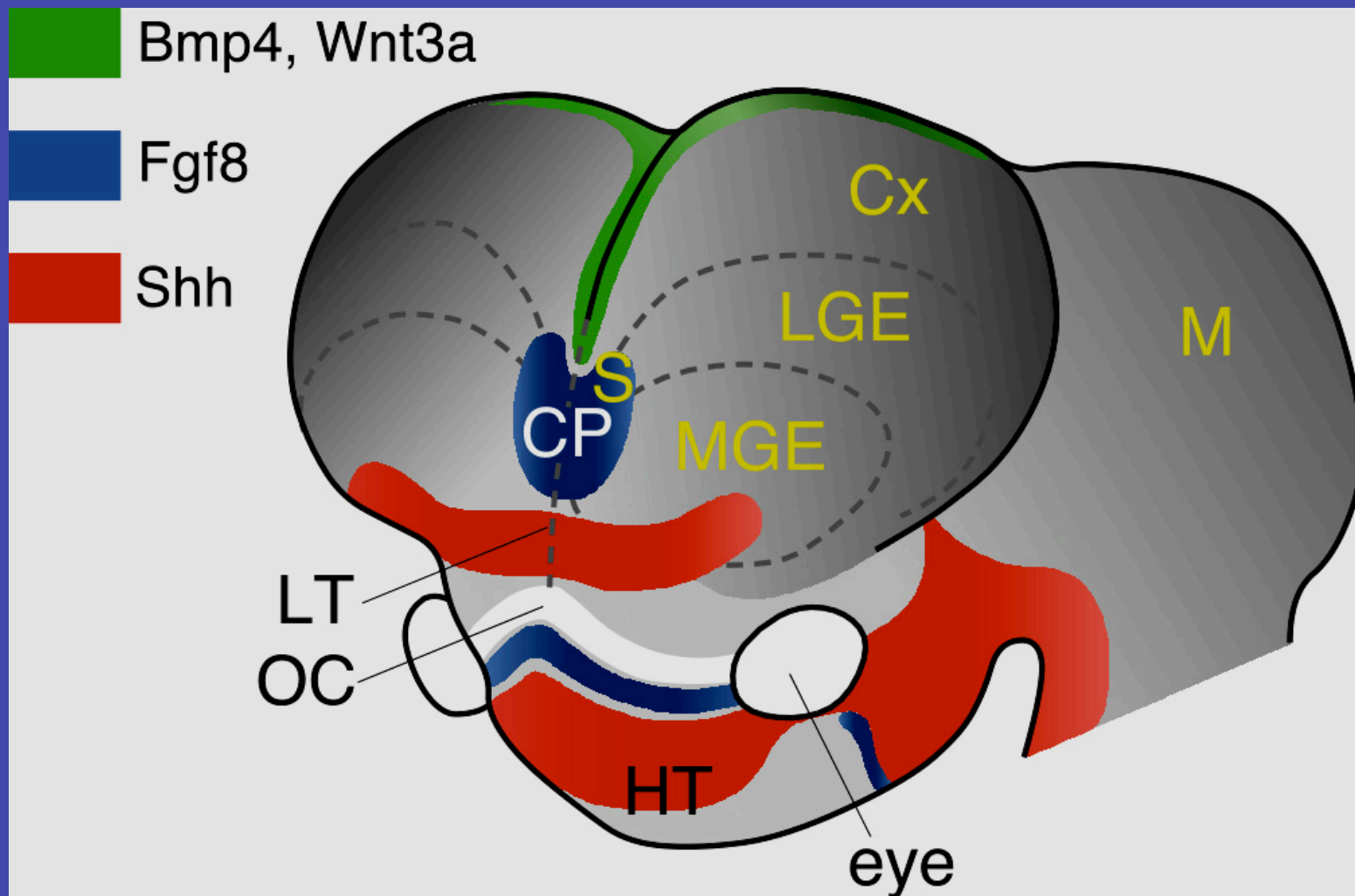


Development of the Cortex

Forebrain patterning

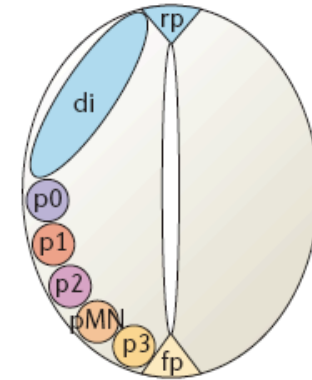
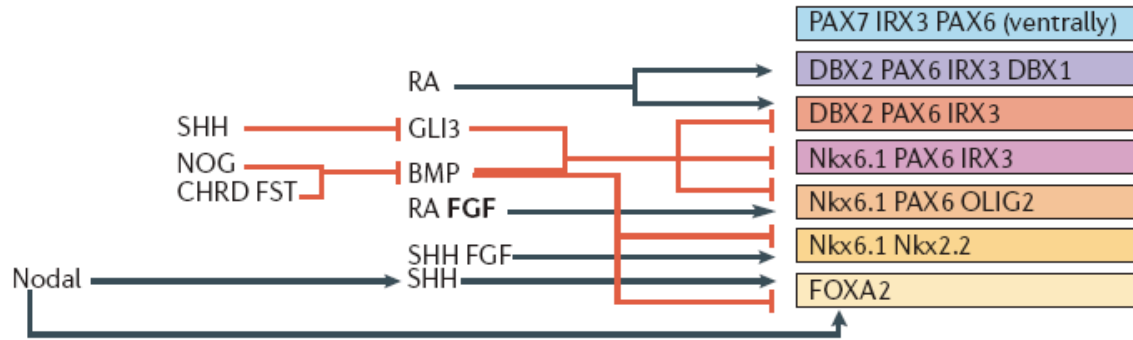


Patterning Centers in the Forebrain

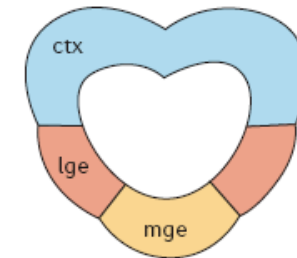
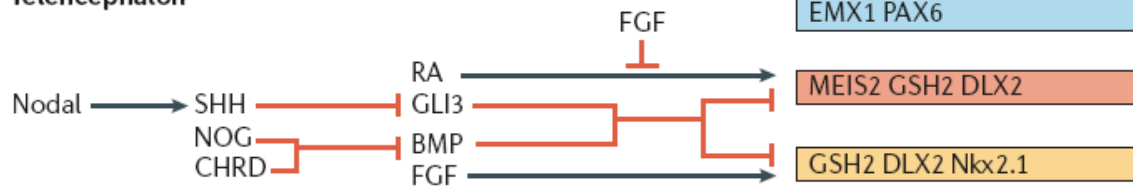


How does this happen?

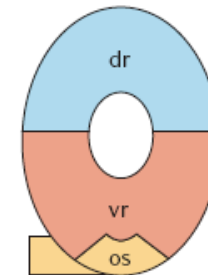
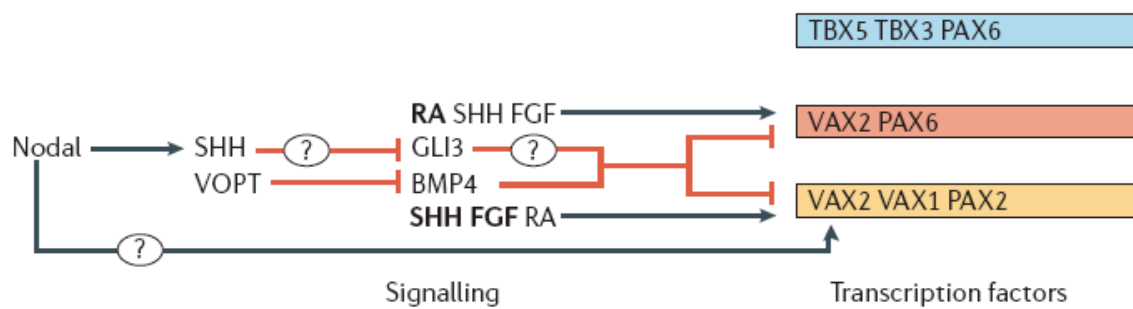
a Spinal cord



b Telencephalon



c Eye

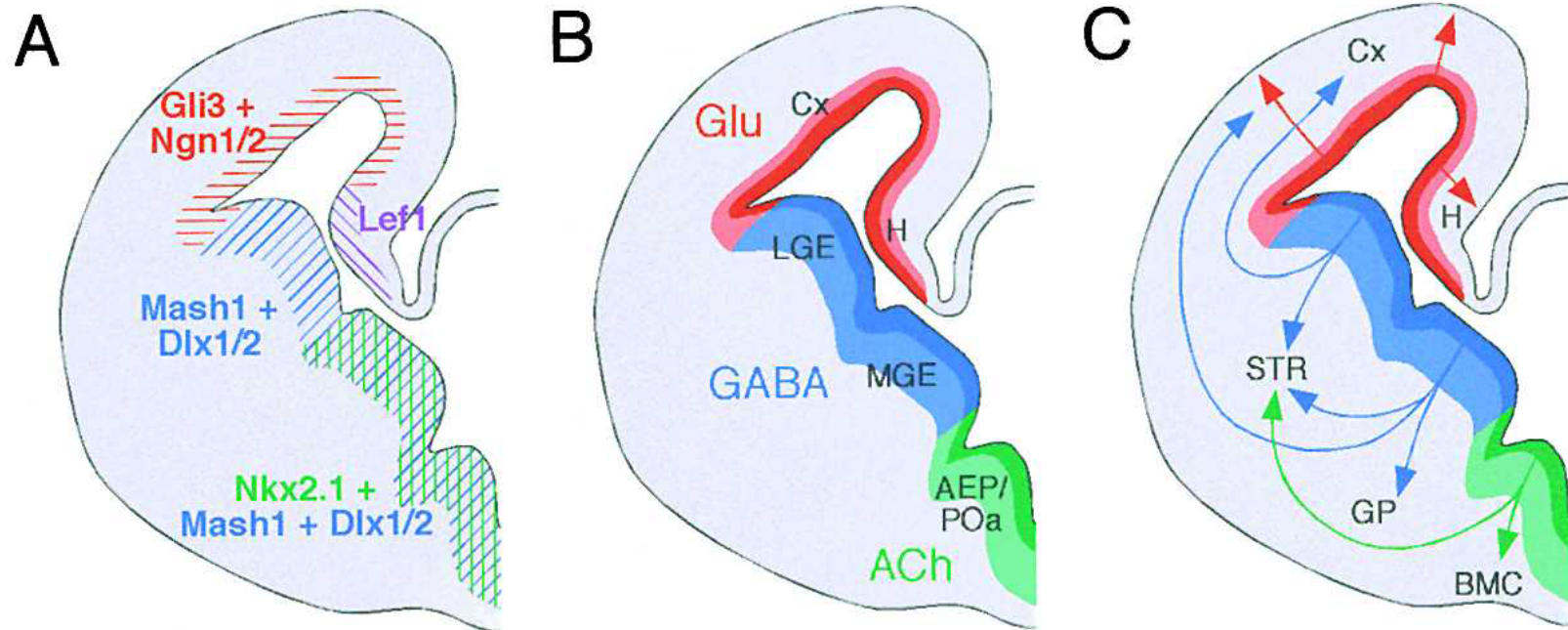


Signalling

Transcription factors

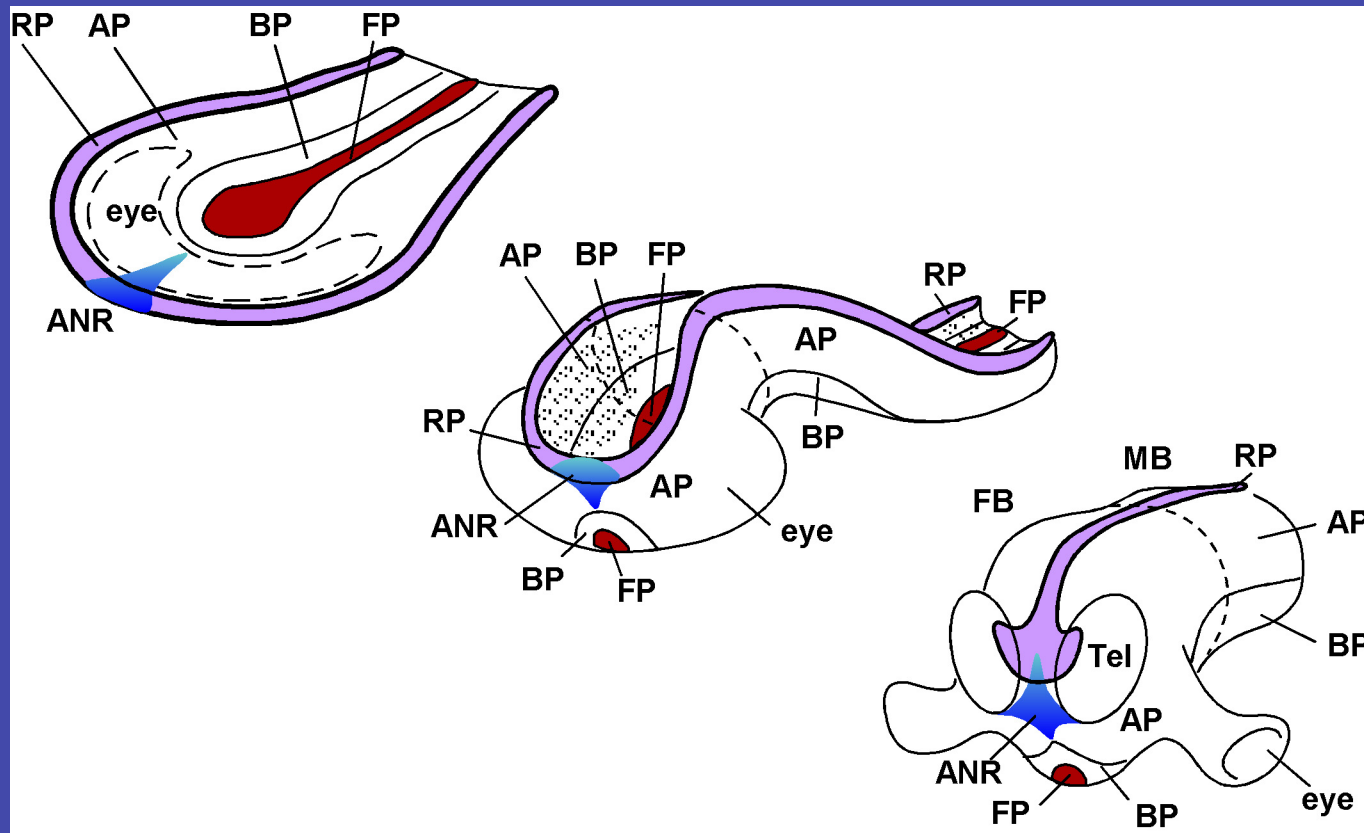
DV patterning

Forebrain progenitor zone domains



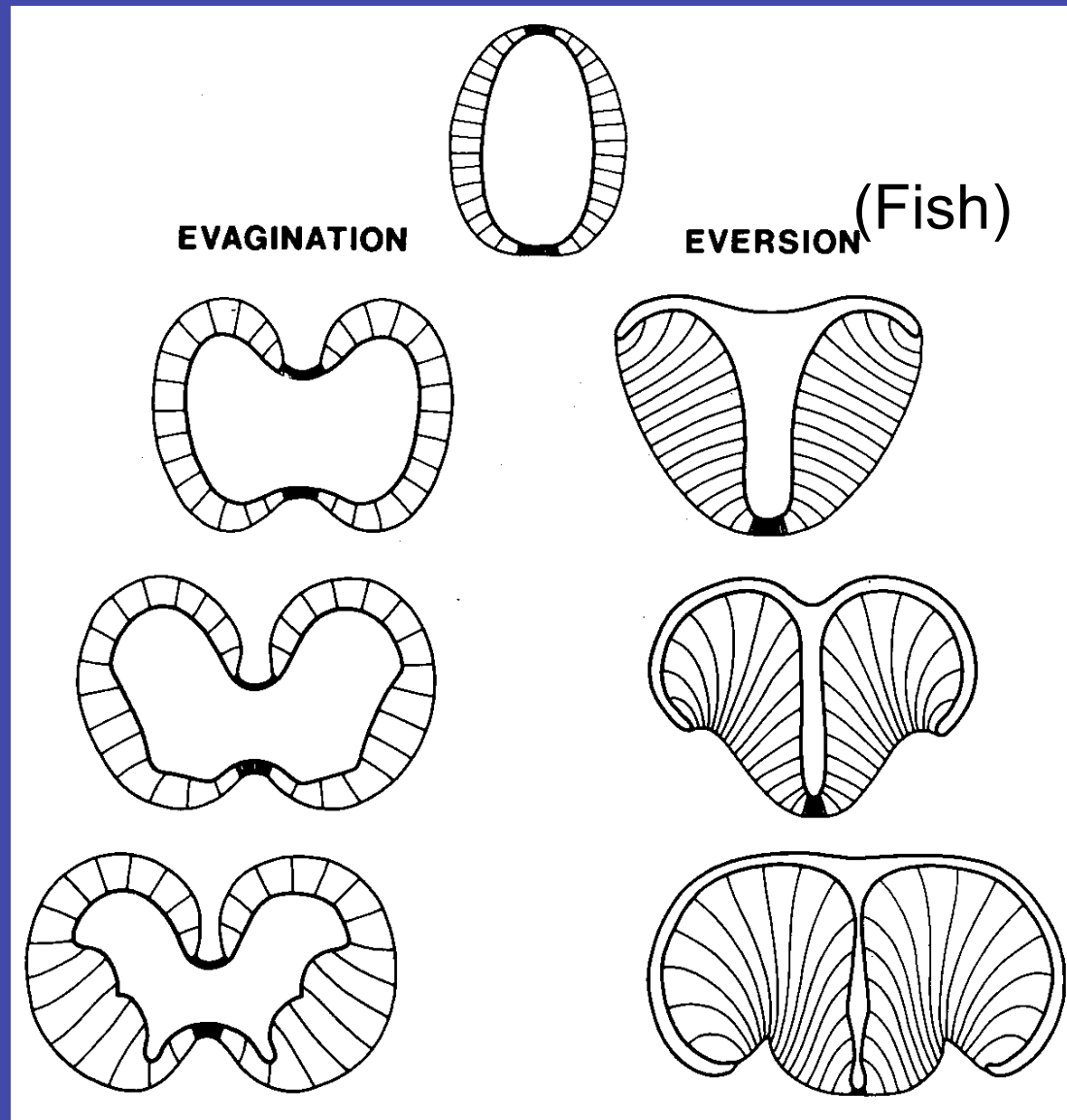
Neural Plate Patterning Centers Longitudinal Zones Neurulation

Evagination of Optic and Telencephalic Vesicles

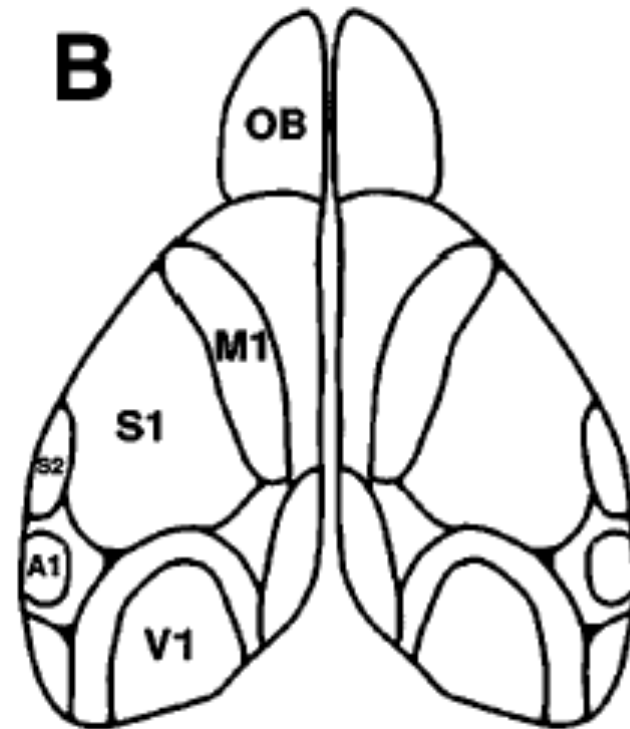
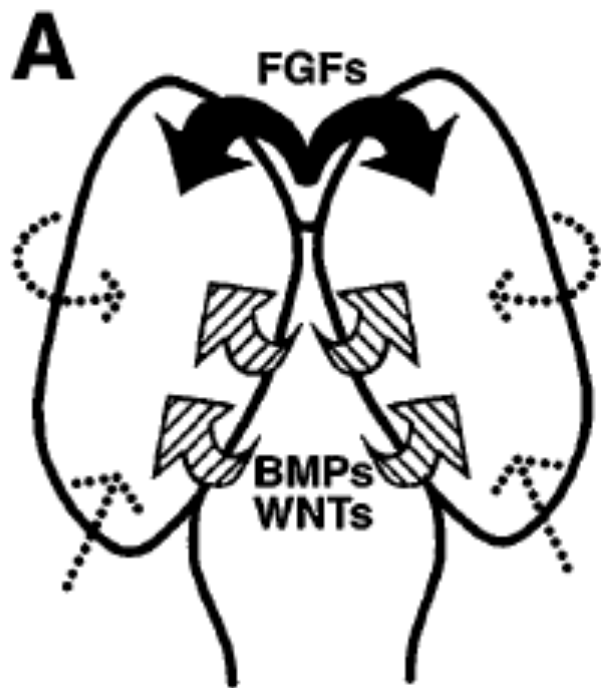


Rubenstein and Puelles, 2003

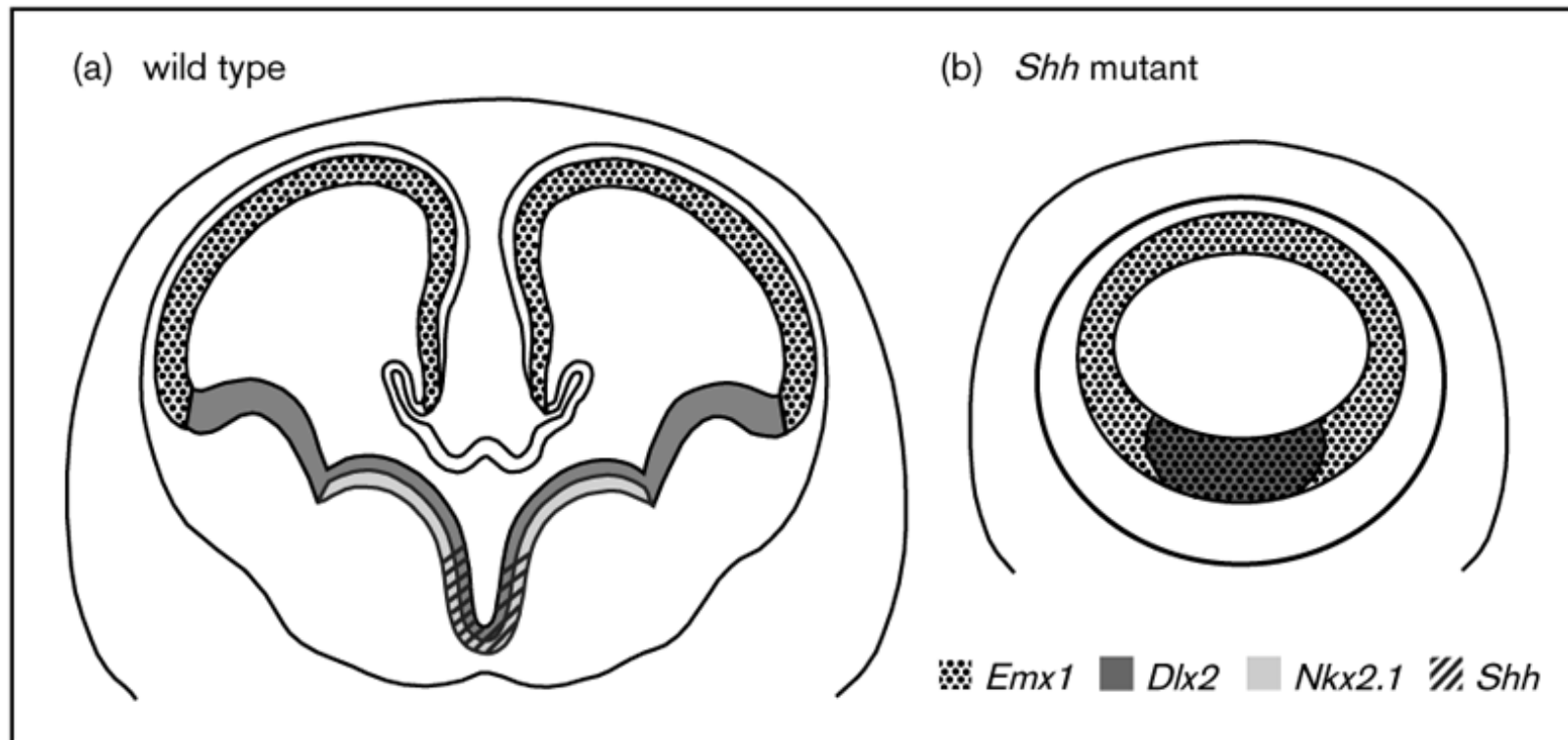
Diverse Modes of Morphogenesis of the Telencephalon in Vertebrates



Cortical signaling centers

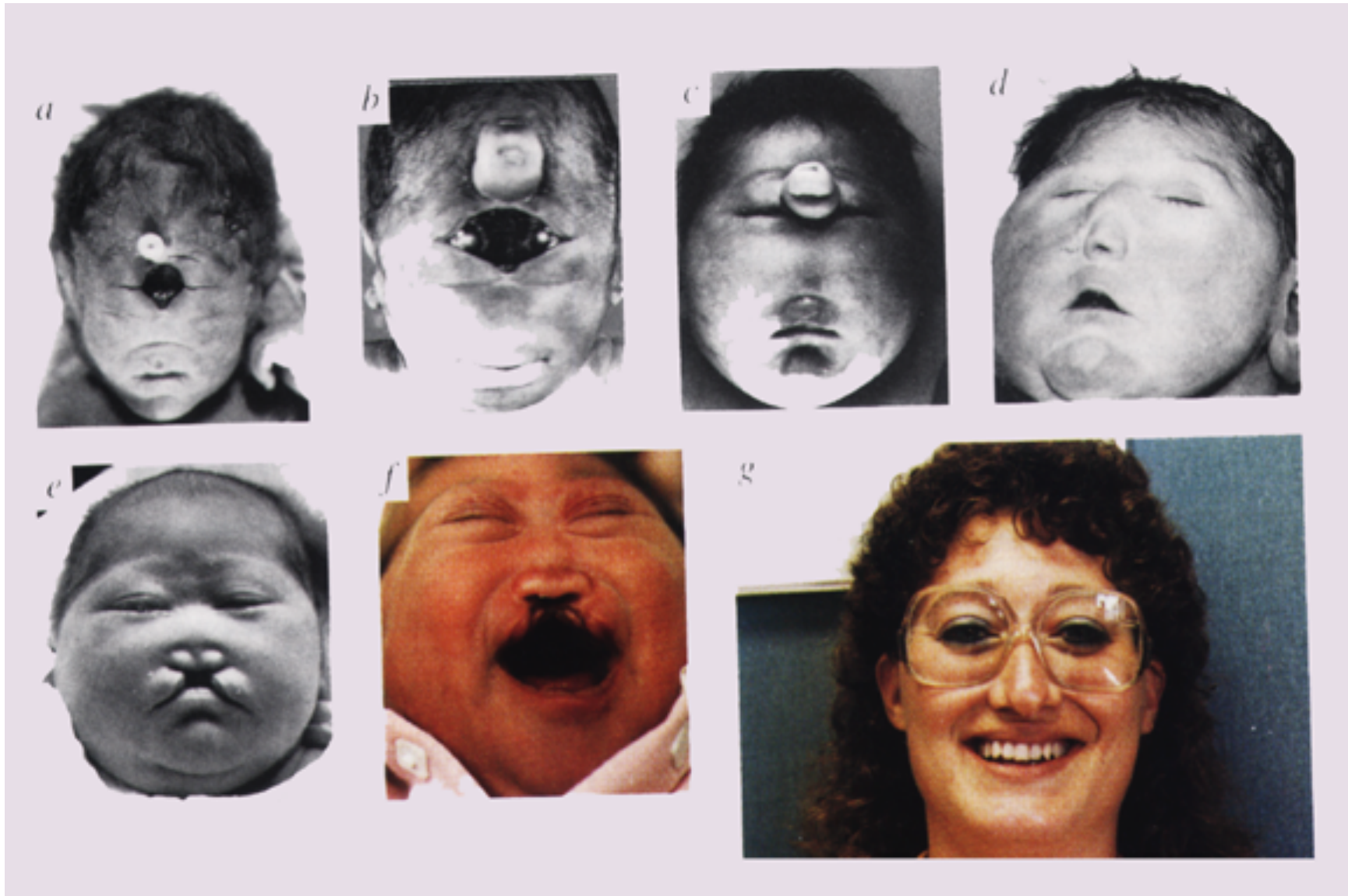

When forebrain patterning goes awry - Holoprosencephaly

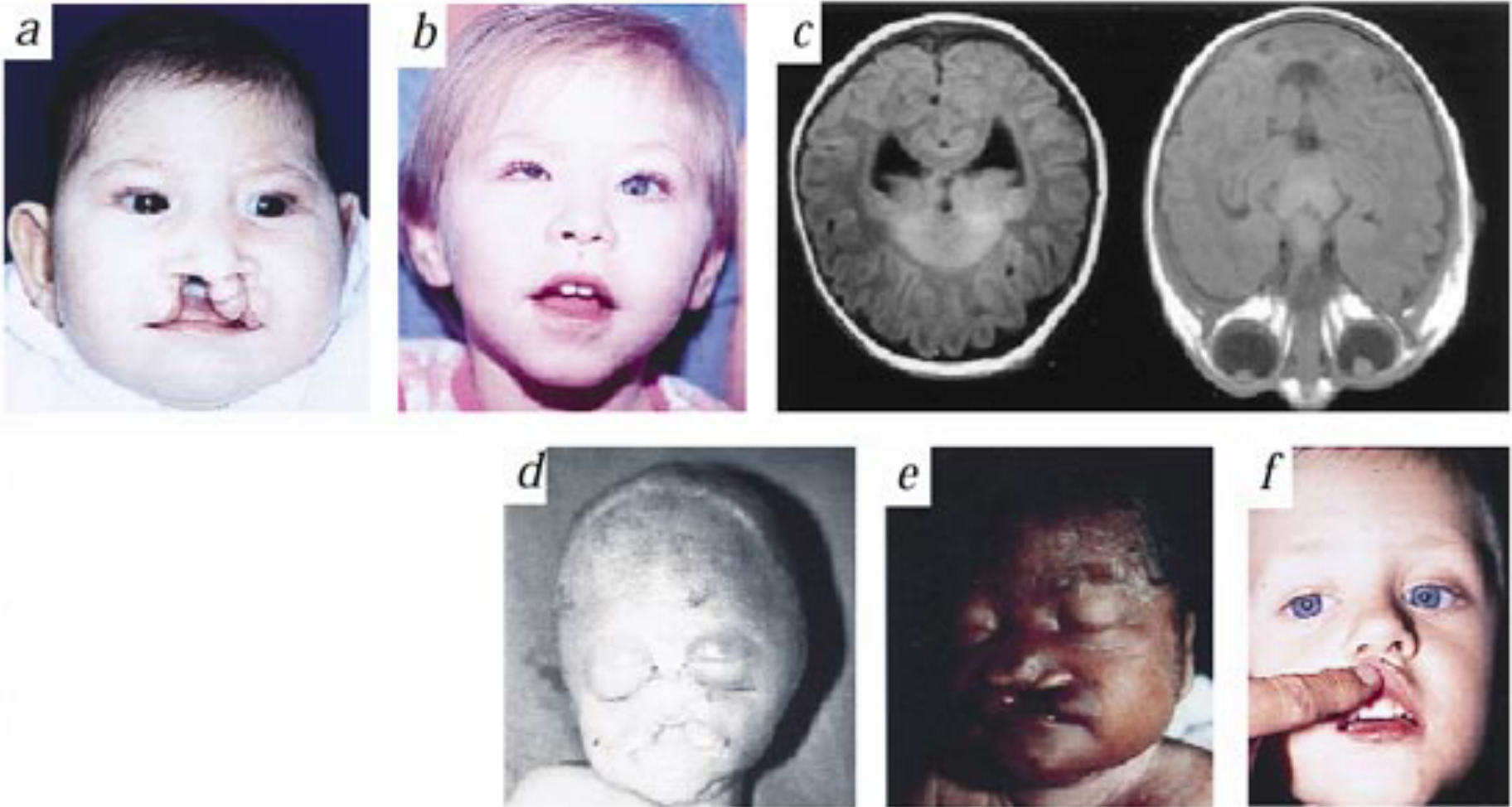


Amazingly common, many loci

Human Shh mutants



Human Six3 mutants



HPE pathology

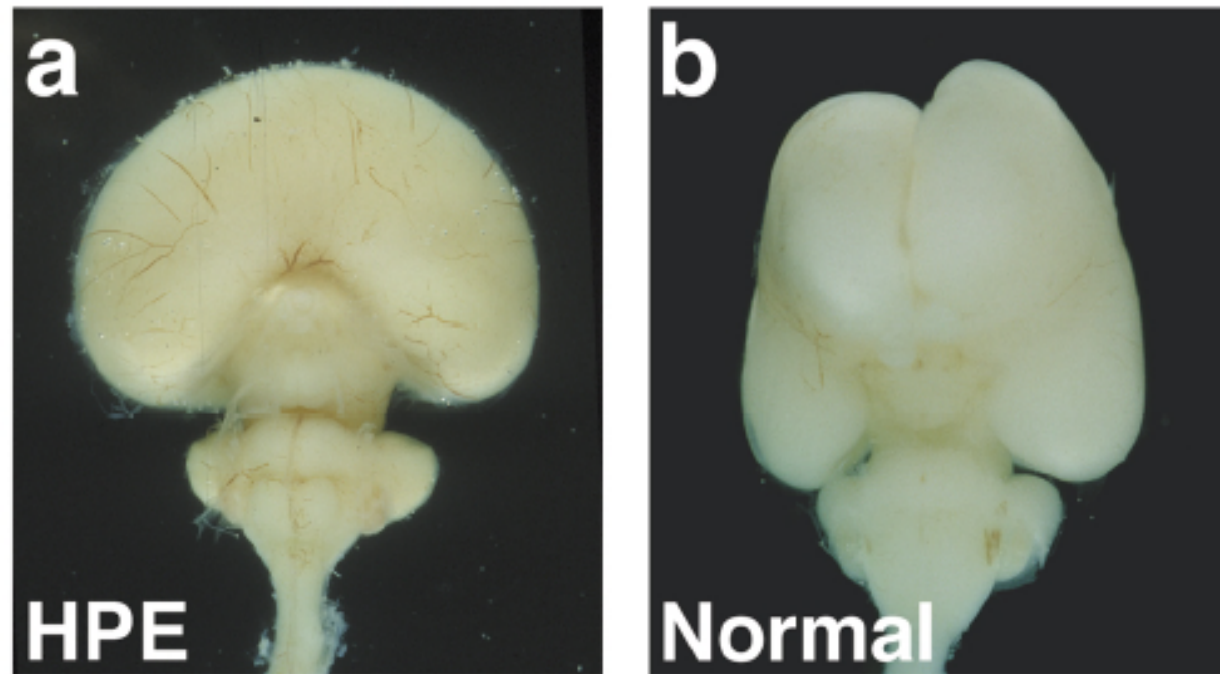
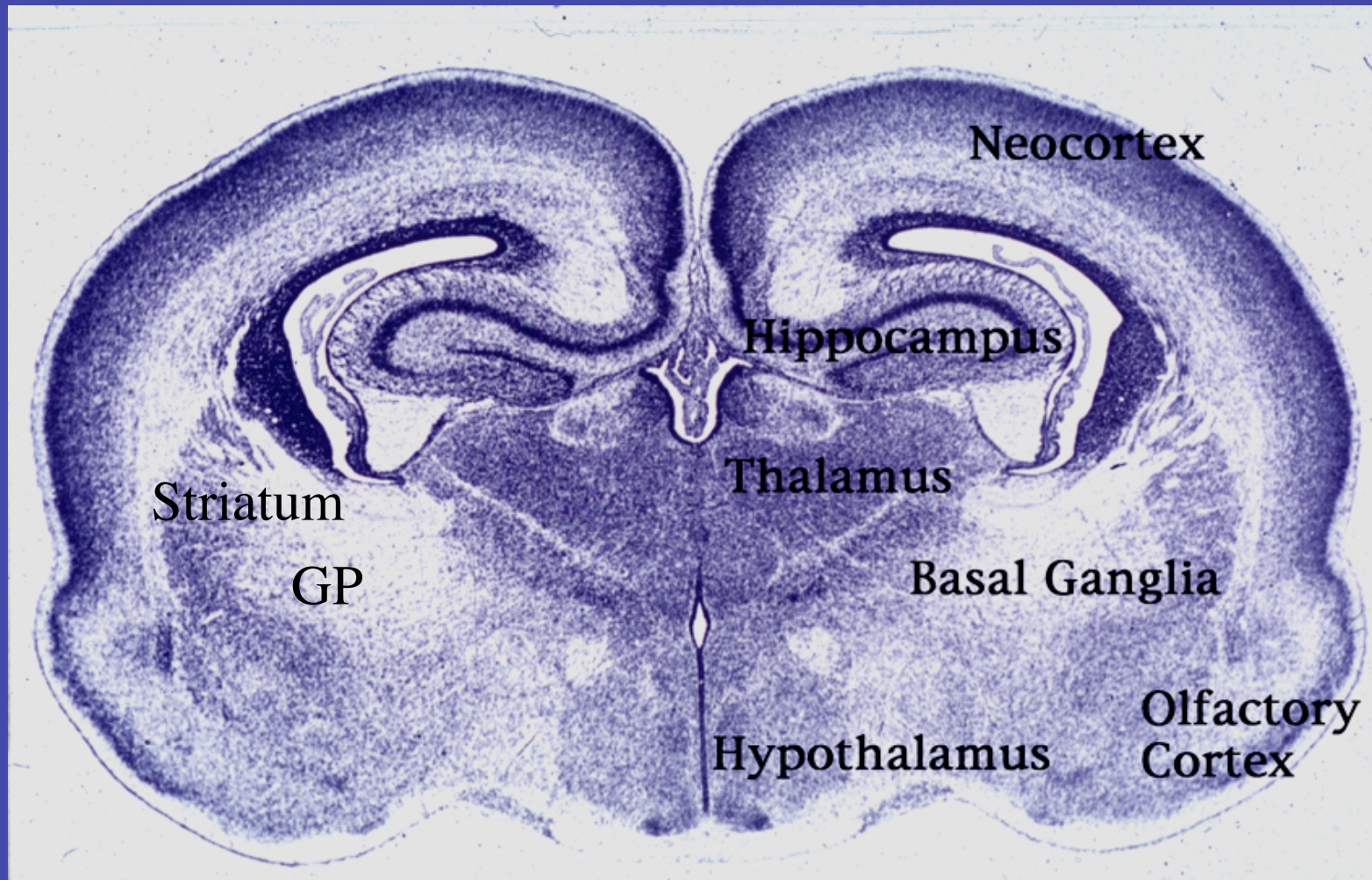
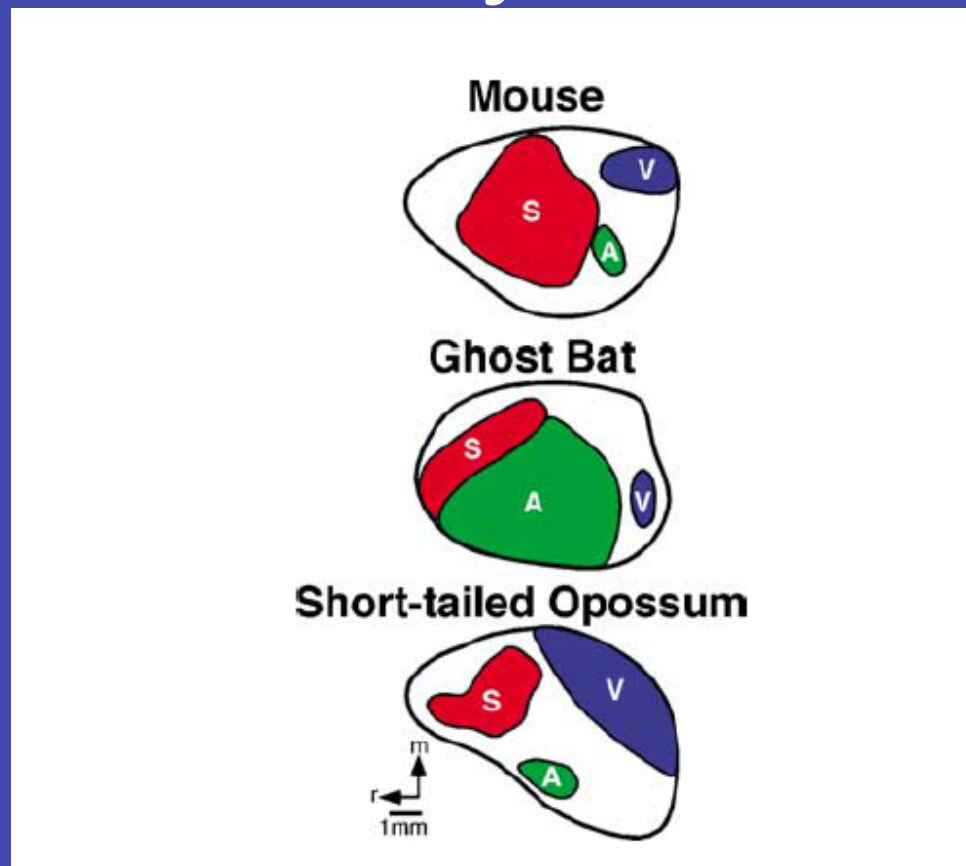


Fig. 4. Human holoprosencephaly. Anterior views of the CNS from an 18-week gestation human fetus with holoprosencephaly (**a**) and a normal 13-week fetus (**b**). The fetus with holoprosencephaly has a single forebrain vesicle ('holosphere') and a cortex that is continuous across the dorsal midline, due to the lack of relative invagination of the roof plate region.

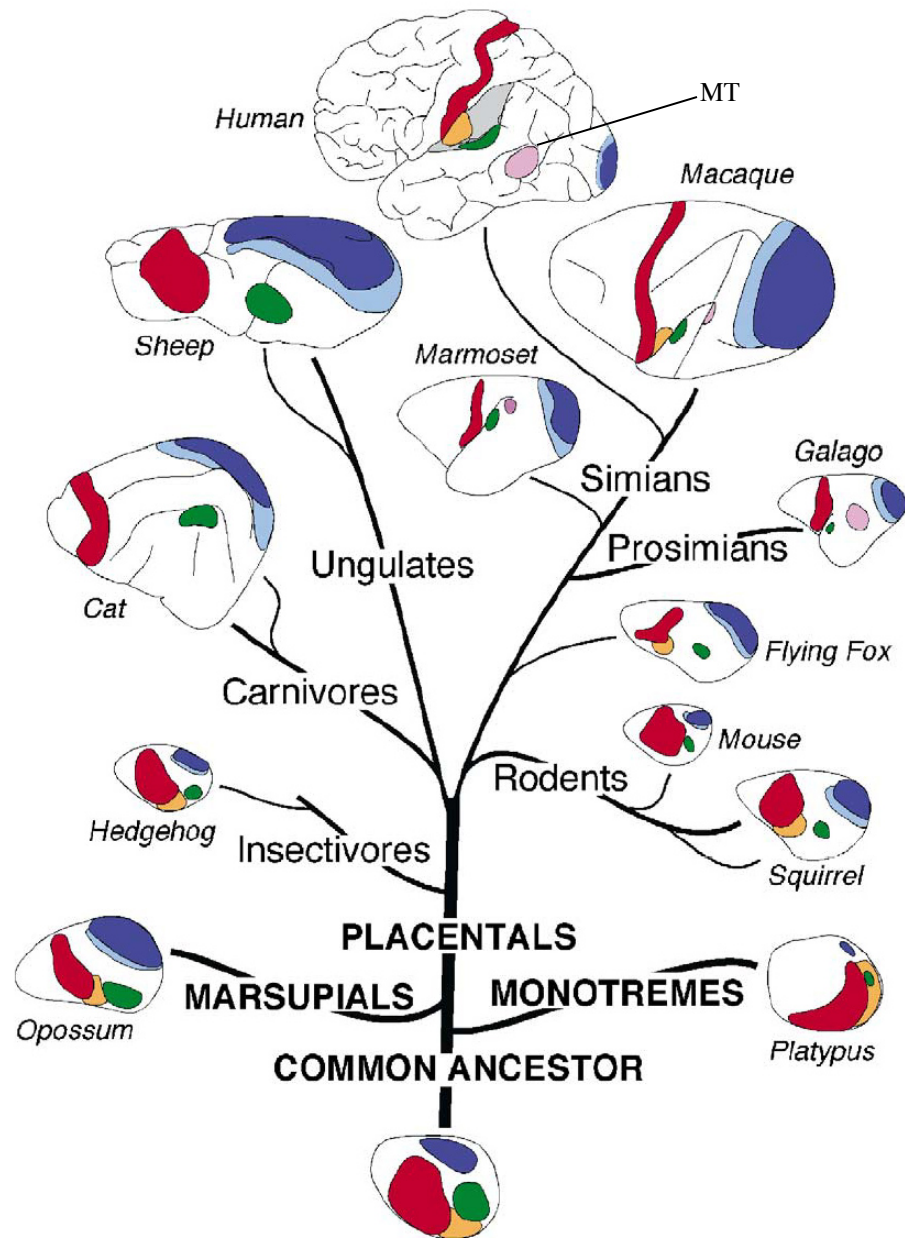
Neonatal Rodent Forebrain: “Dorsoventral” Subdivisions of the Cortex



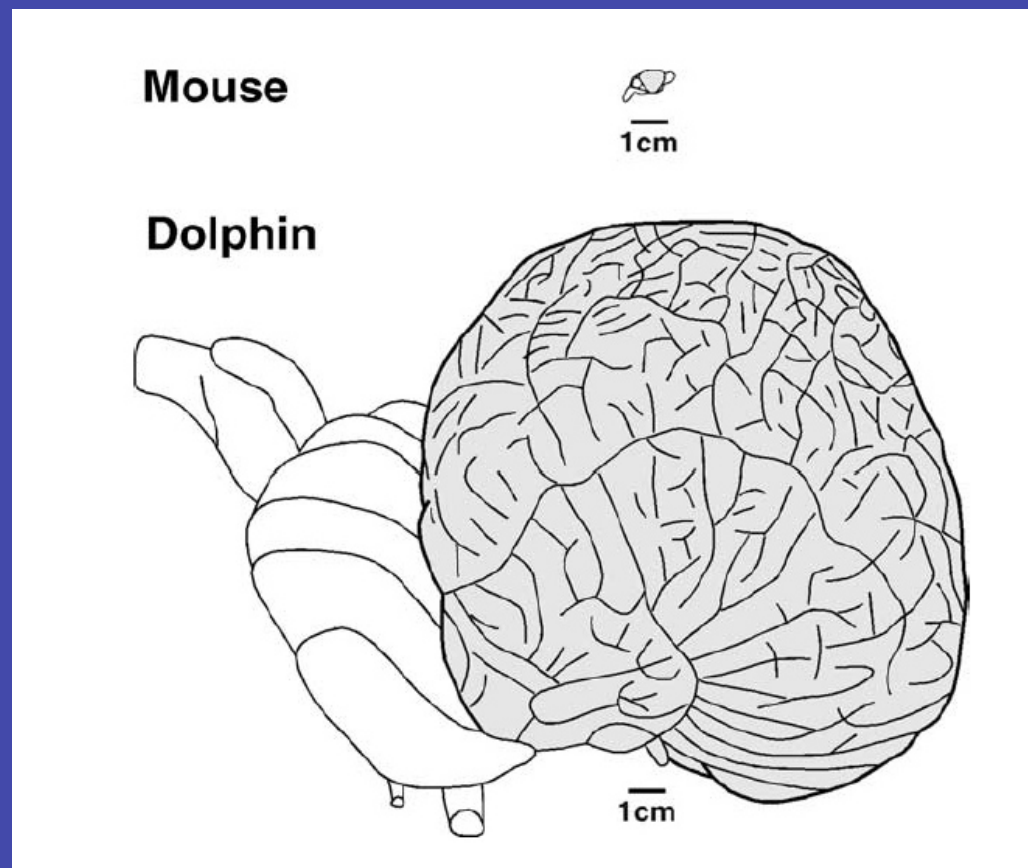
Topographic Conservation of Relative Positions of Primary Sensory Areas



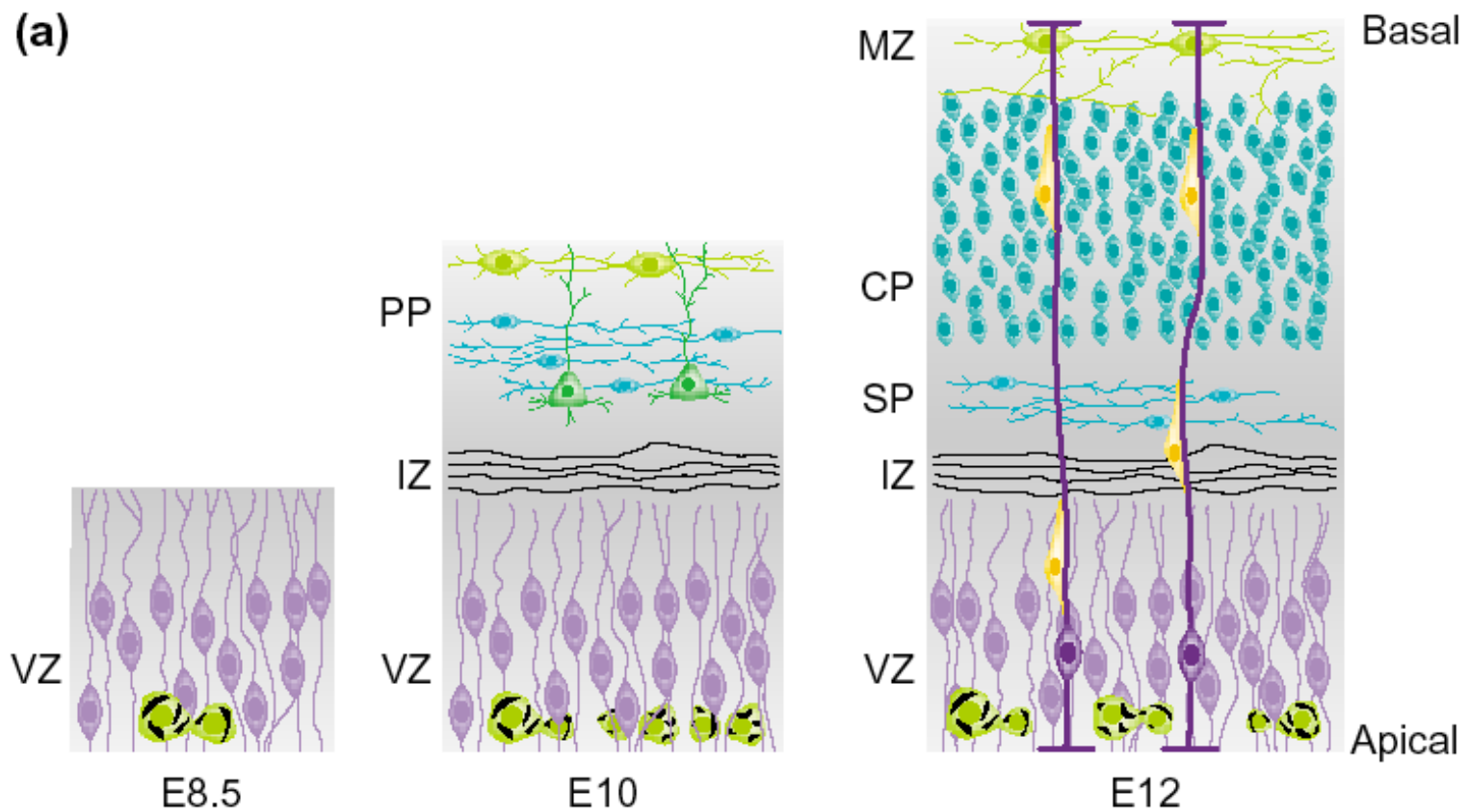
Krubitzer and Kahn, 2003



Control of Cortex Size Is Mediated in Part Through Control of Progenitor Cell Properties



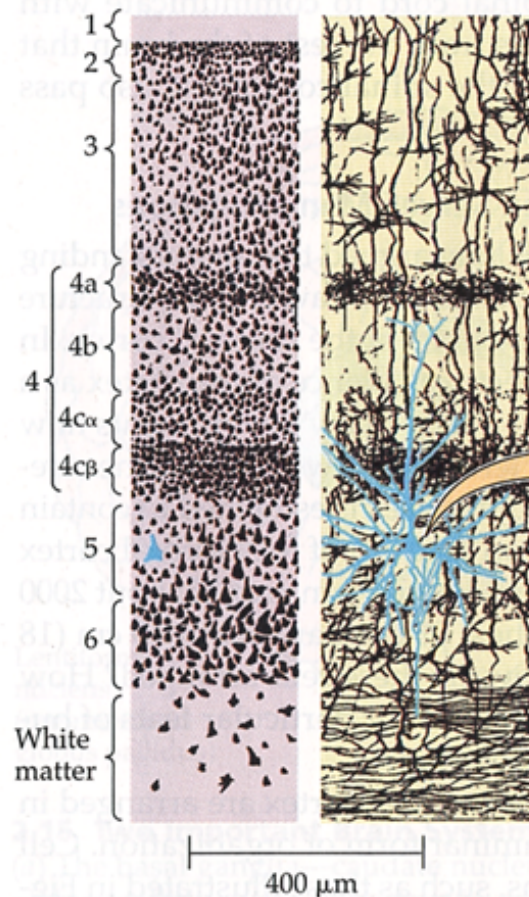
Radial Cortical Organization



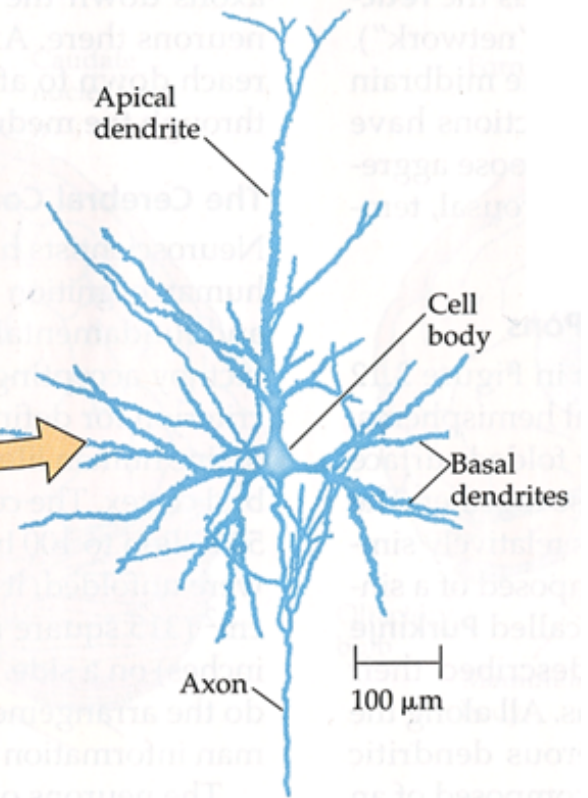
Histology of the Cerebral Cortex

- Neocortex has 6 layers designated I, II, III, IV, V, VI
- Pyramidal cells predominate in layers III and V
- Granule cells in layers II and IV

(a) Six layers of cortex



(b) A single pyramidal neuron

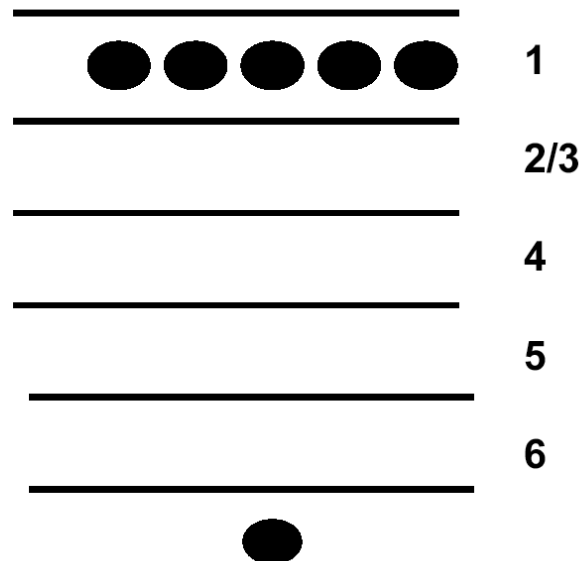


Models of Radial Organization

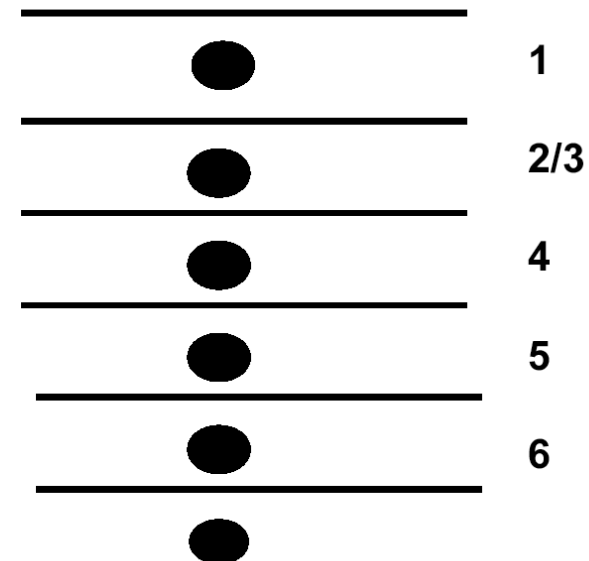
Are there different kinds of progenitors?
(layer 1-specific progenitor)

Does one progenitor make all cell layers?

LINEAGE MODEL



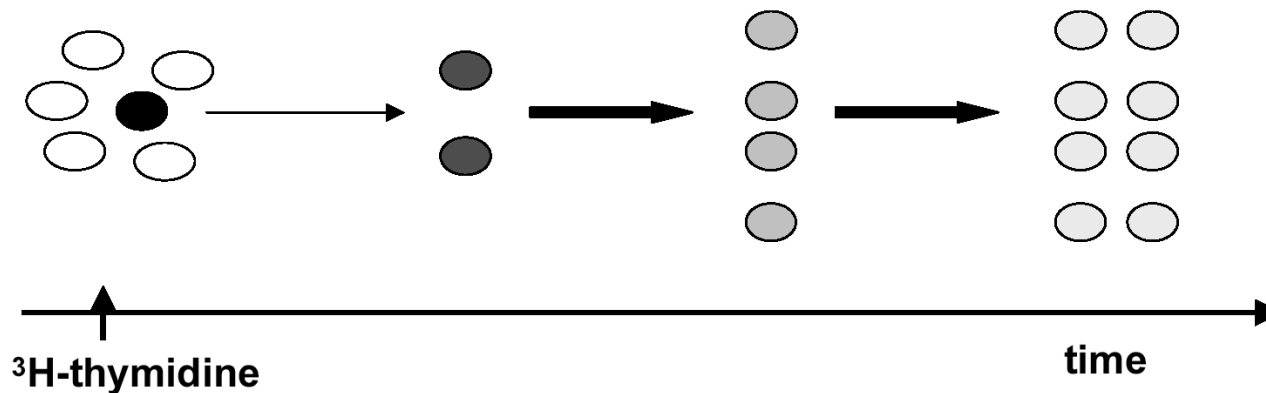
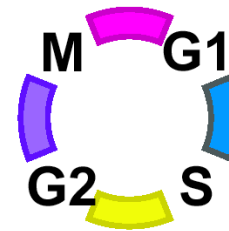
INSTRUCTIONAL MODEL



Birthdating

Neuronal Birthdating with ^3H -thymidine

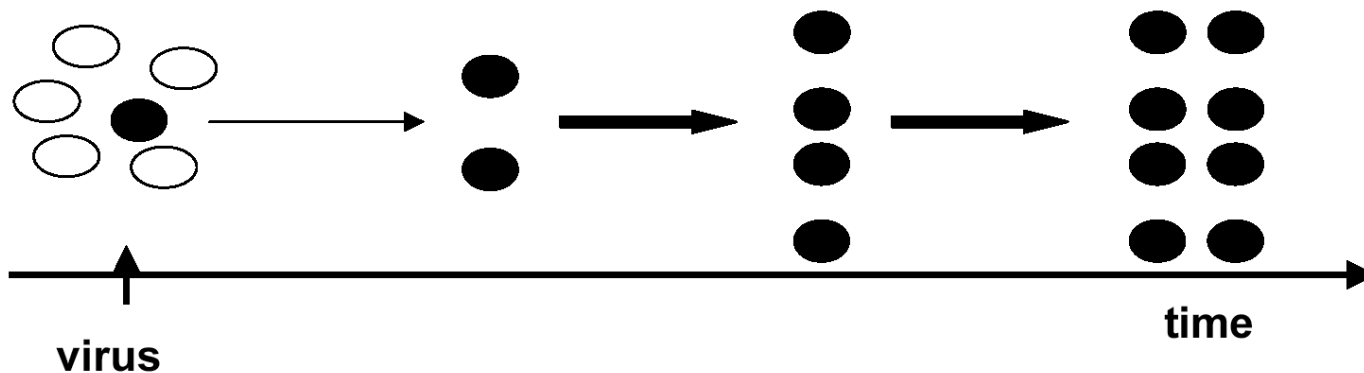
- ^3H -thymidine is incorporated into the DNA during the S-phase (replication of DNA)
- It marks all mitotic cells
- Quantitative technique
- It disappears in ~2-4 generations.



Lineage Tracing

Lineage Tracing


- Use replication incompetent retrovirus (incorporated into a cell's genomic DNA but not infectious)
- The virus DNA will be inherited by all the daughter cells (it doesn't become diluted)



Are there layer specific progenitors?

Are there layer-specific progenitors?

Expt: Use lineage tracing to label single neurons and follow their progeny.

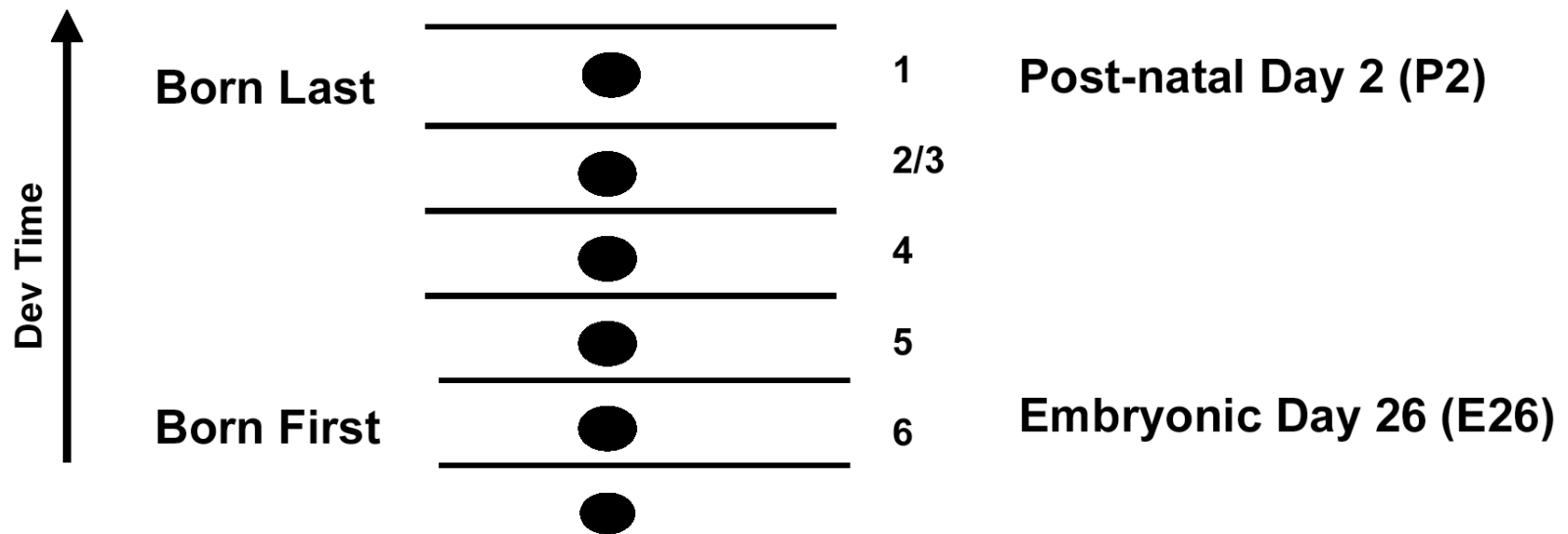


Result: Single cells generate neurons in multiple layers.

What is the timing?

Different layers form at different developmental times

“Inside First-Outside Last” development of cortical layers



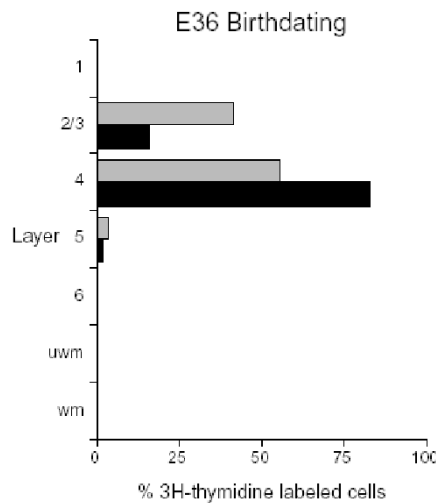
Young precursors are plastic

Does the environment instruct the layer fate?

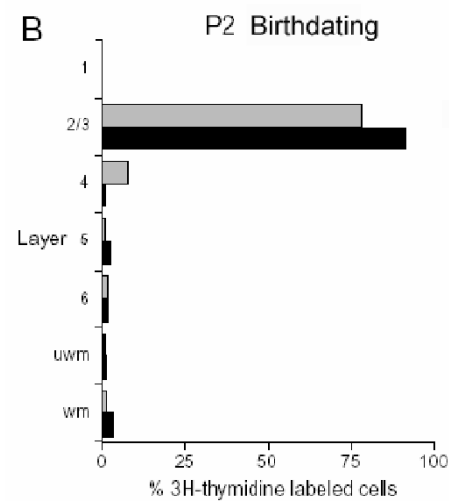
Expt: Transplant Progenitor cells from early stage to late stage

What would they normally become?

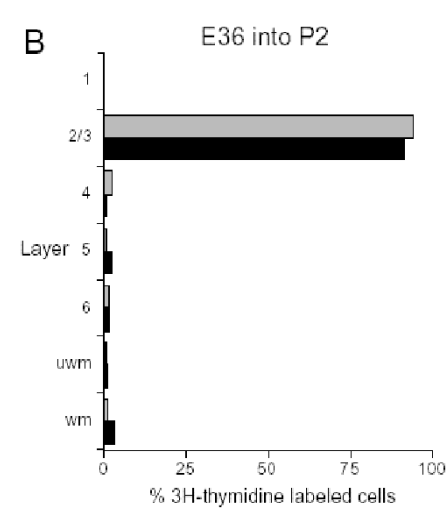
What do they become when the host environment is changed?



Most are layer 4



Most are layer 2/3



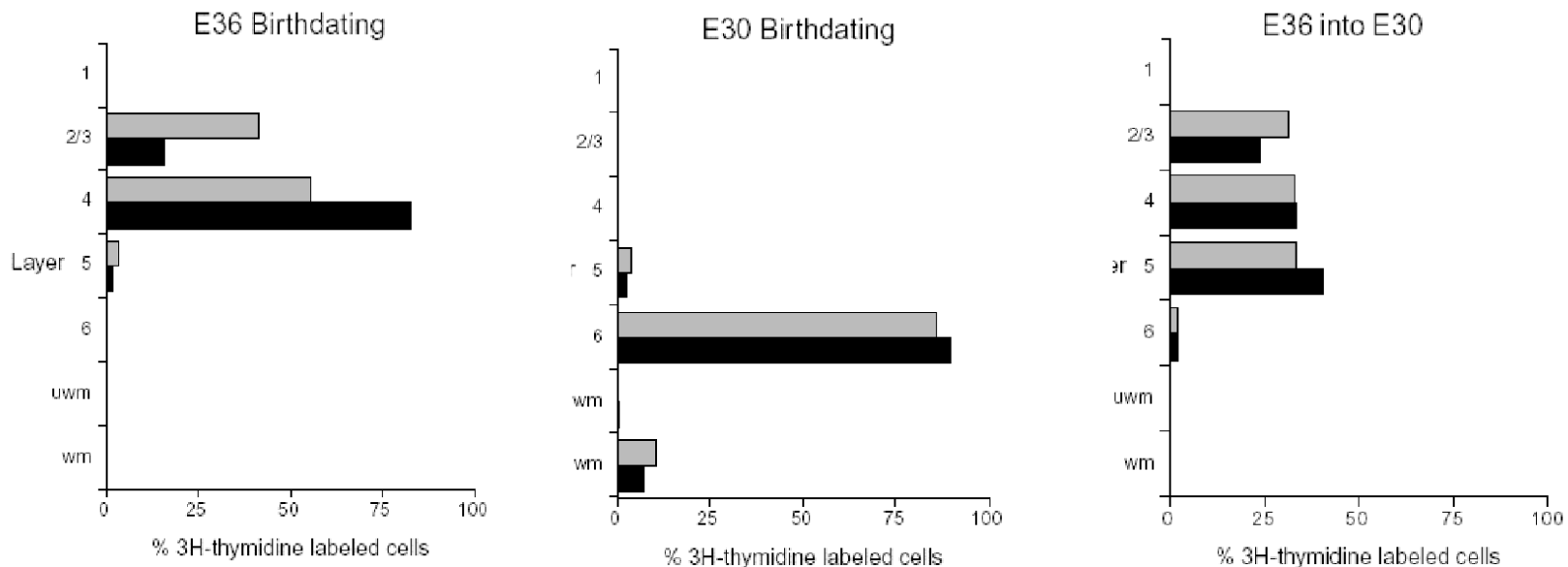
Most are layer 2/3

Precursors age through gestation

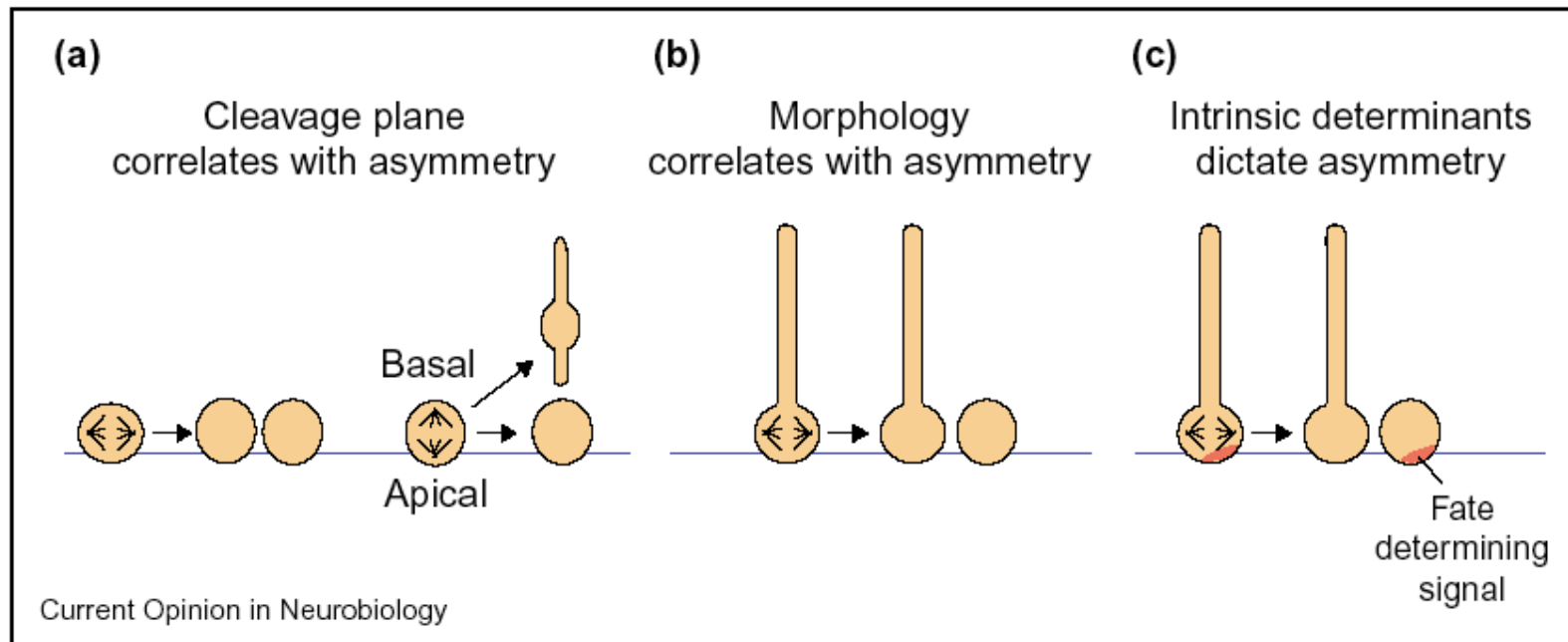
Expt: Transplant Progenitor cells from late stage to early stage

What would they normally become?

What do they become when the host environment is changed?

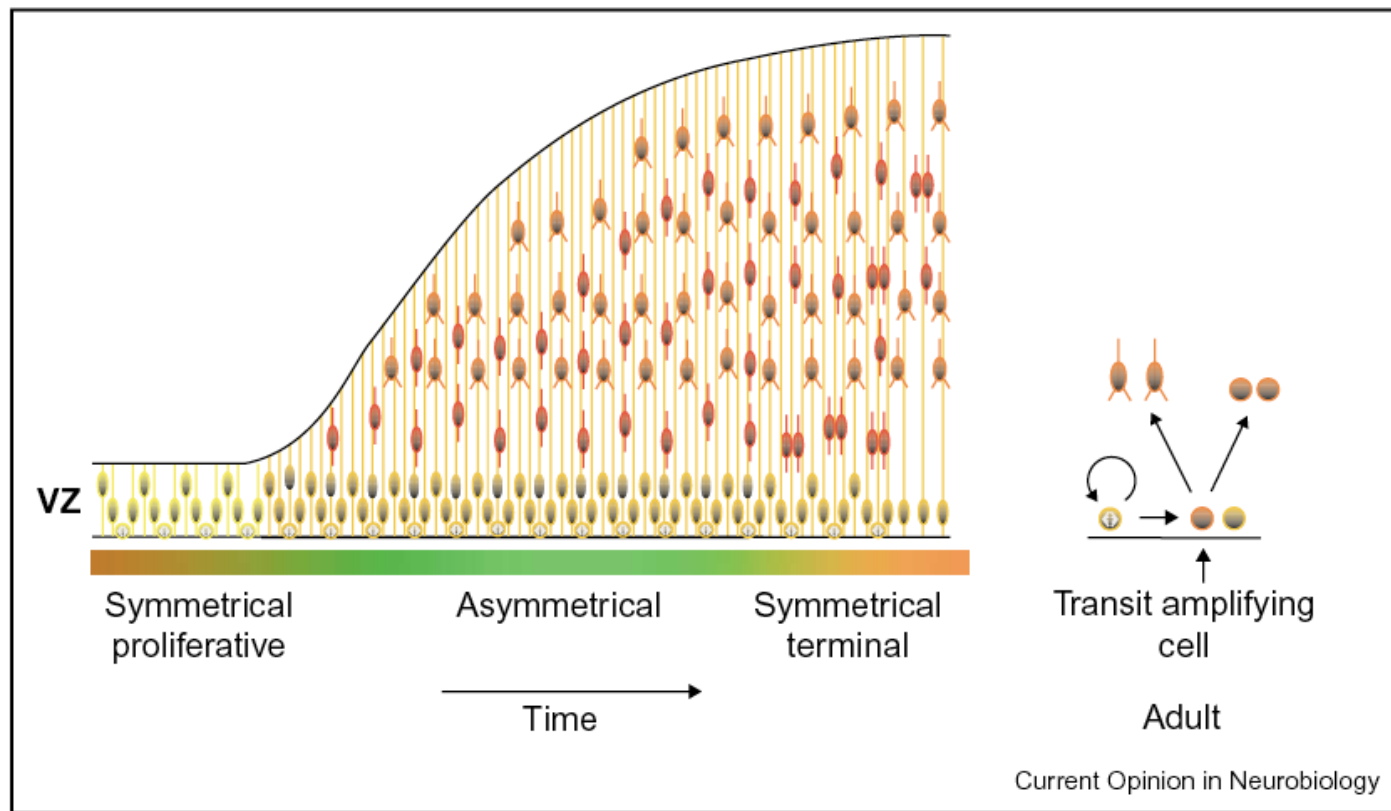


How might this work?



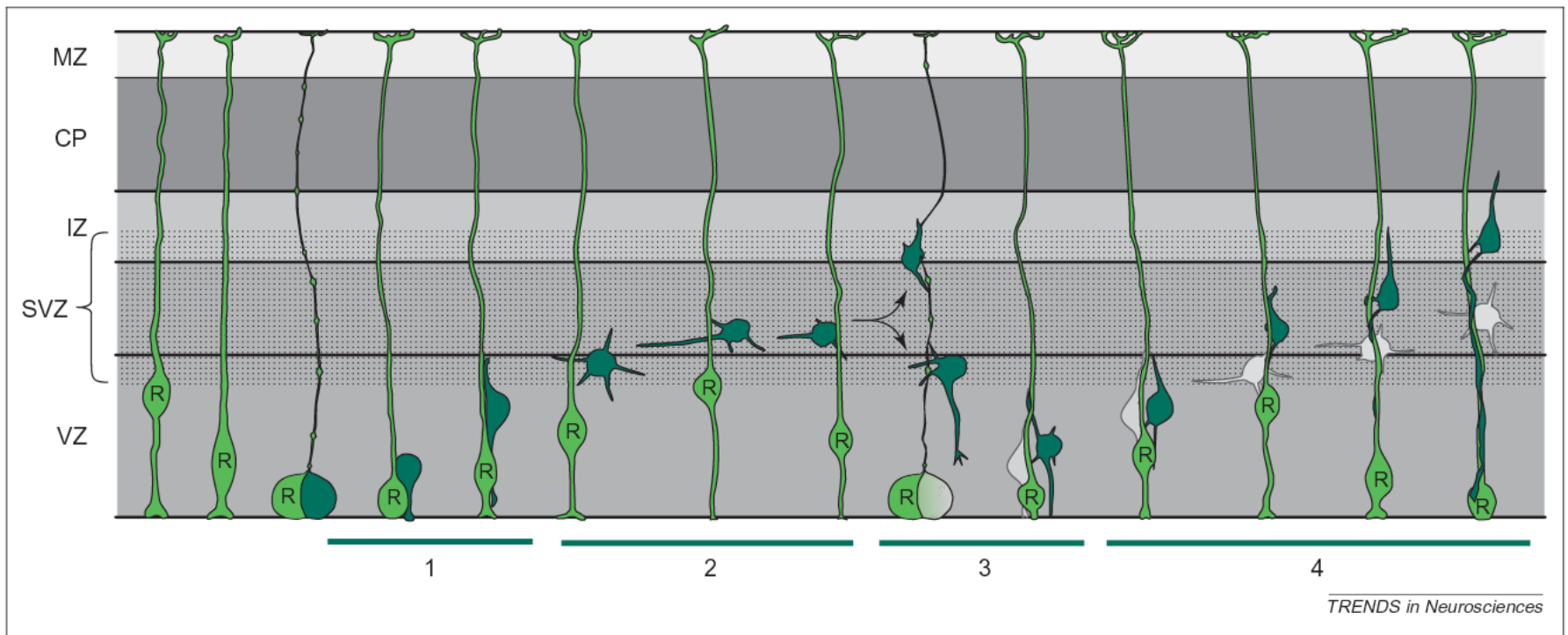
Asymmetric divisions plus a clock account for this phenomenon

Temporal Control of Symmetrical and Asymmetrical Mitoses



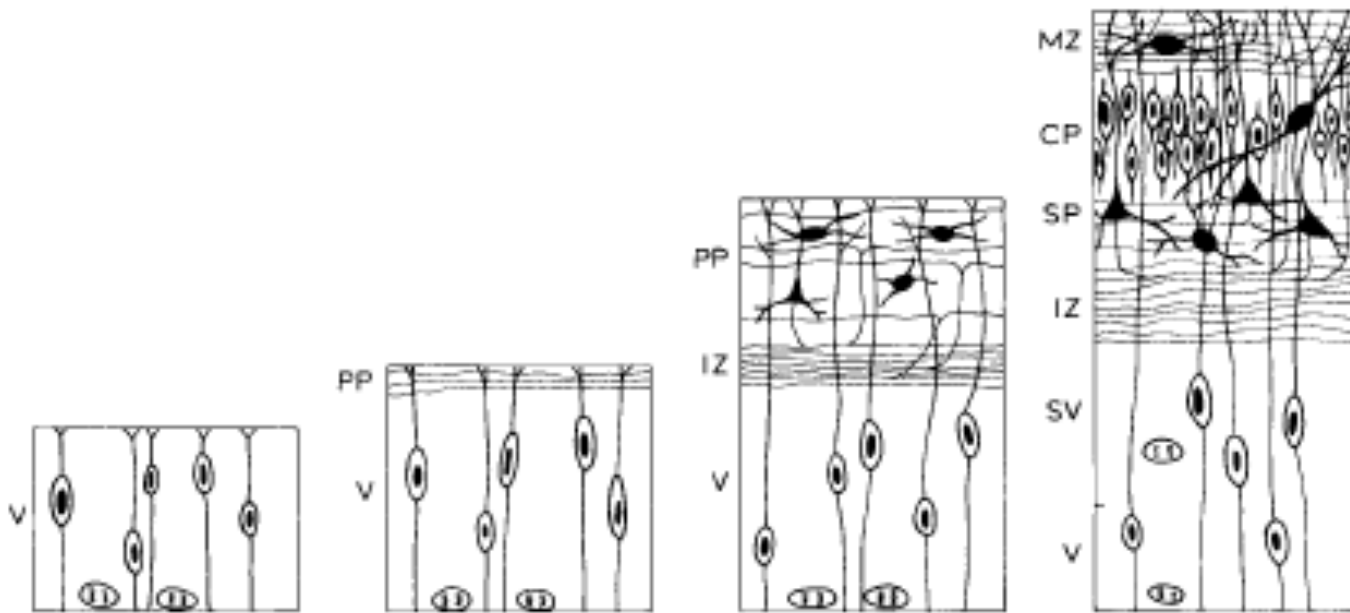
Fishell and Kriegstein, 2003

Time of leaving the cell cycle correlates with laminar fate



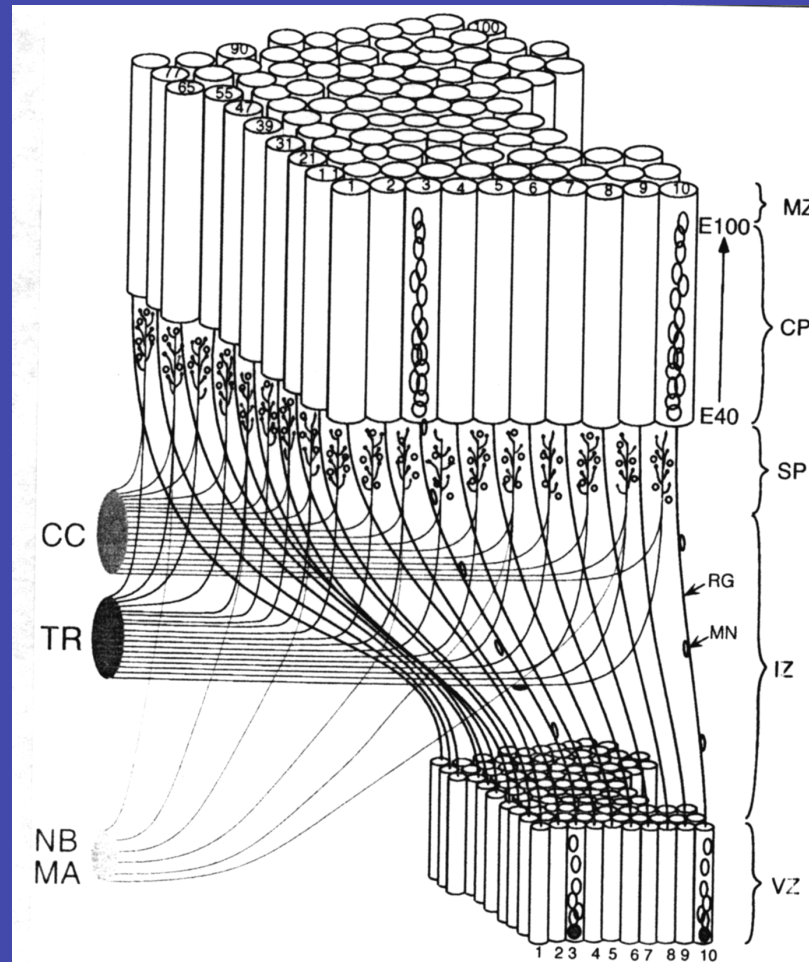
Earliest: Preplate
Middle: Deep layers
Late: Superficial layers

Early Development of the Cortex: Preplate, Cortical Plate, Marginal Zone and Subplate



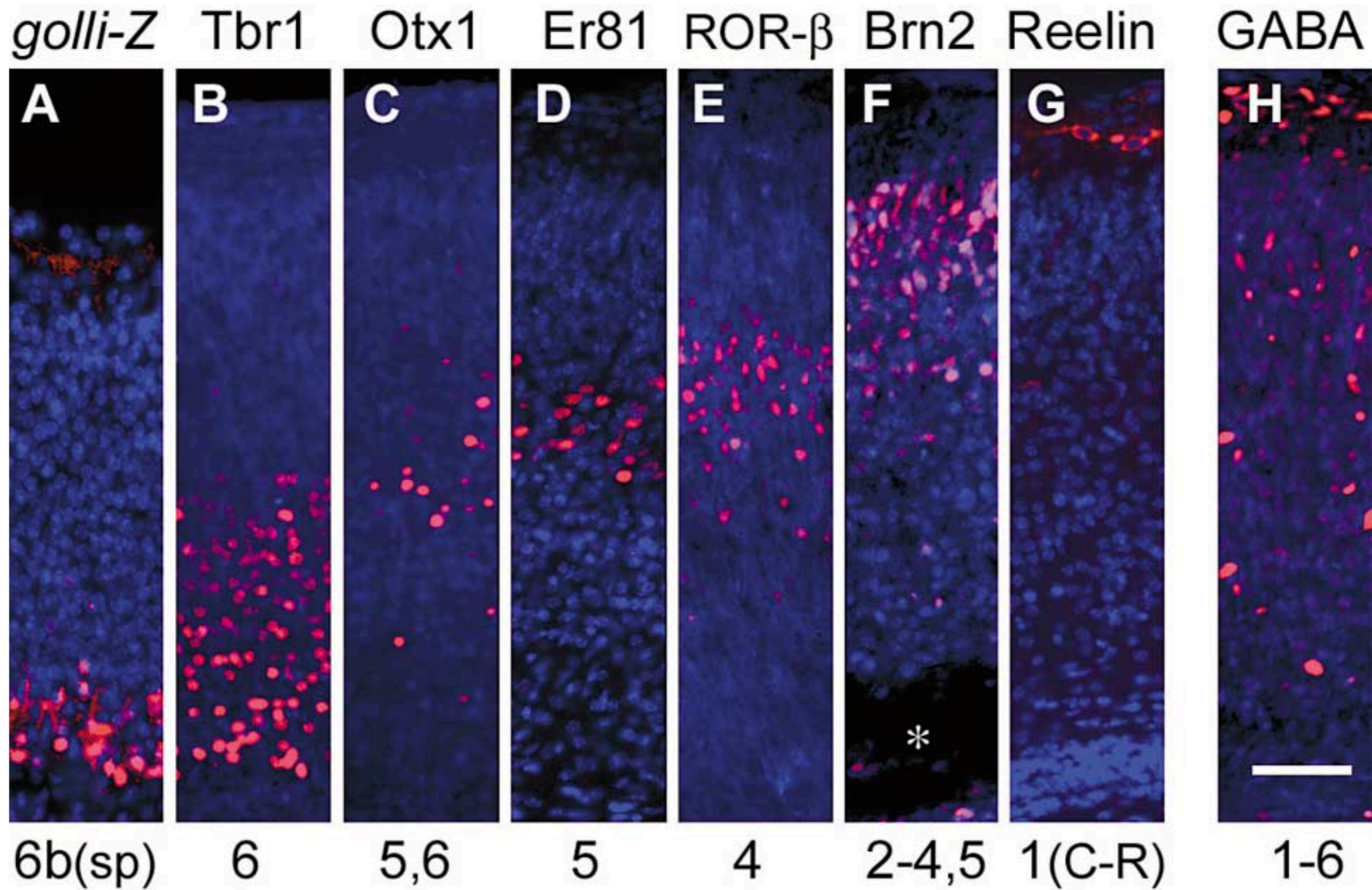
Uylings et al., 1990

Genesis of Cortical Neurons: Inside-Out laminar organization



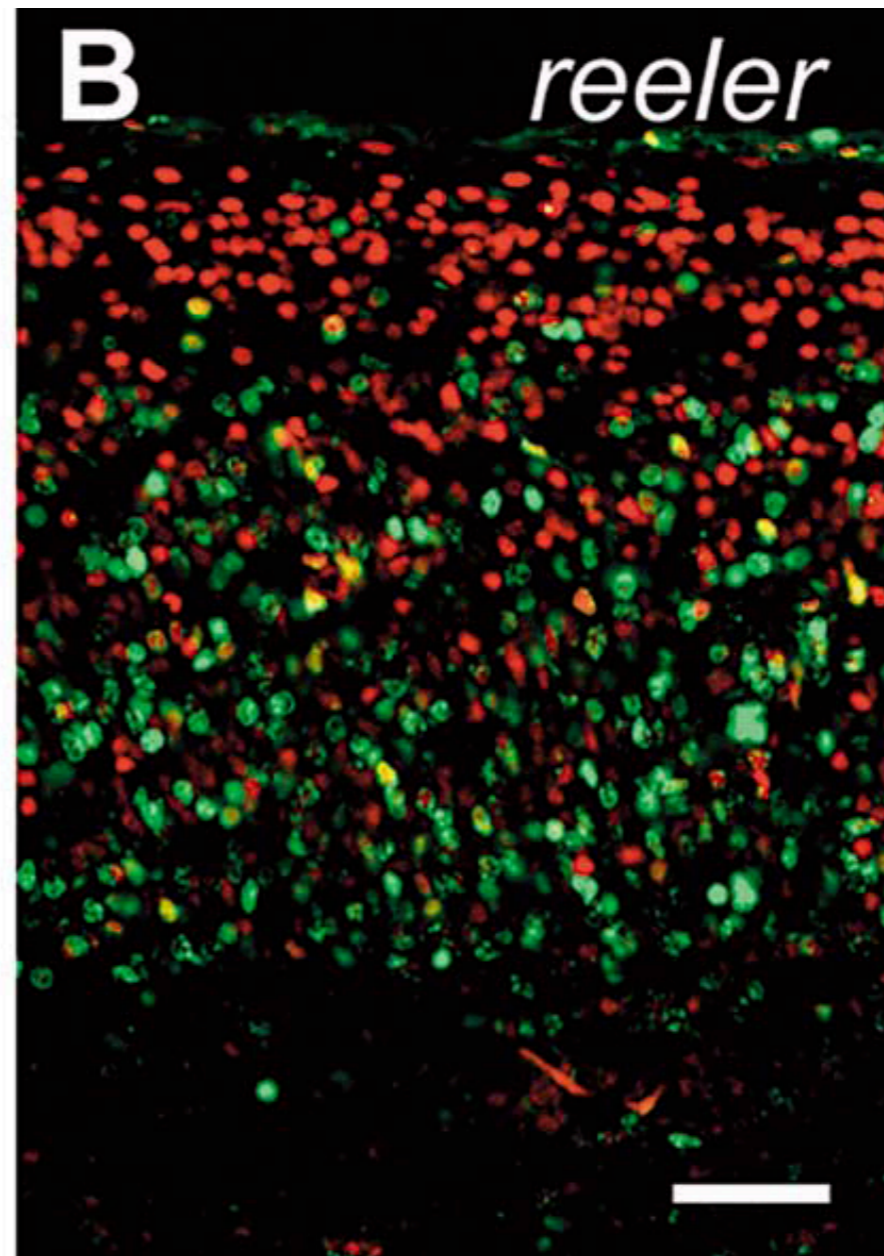
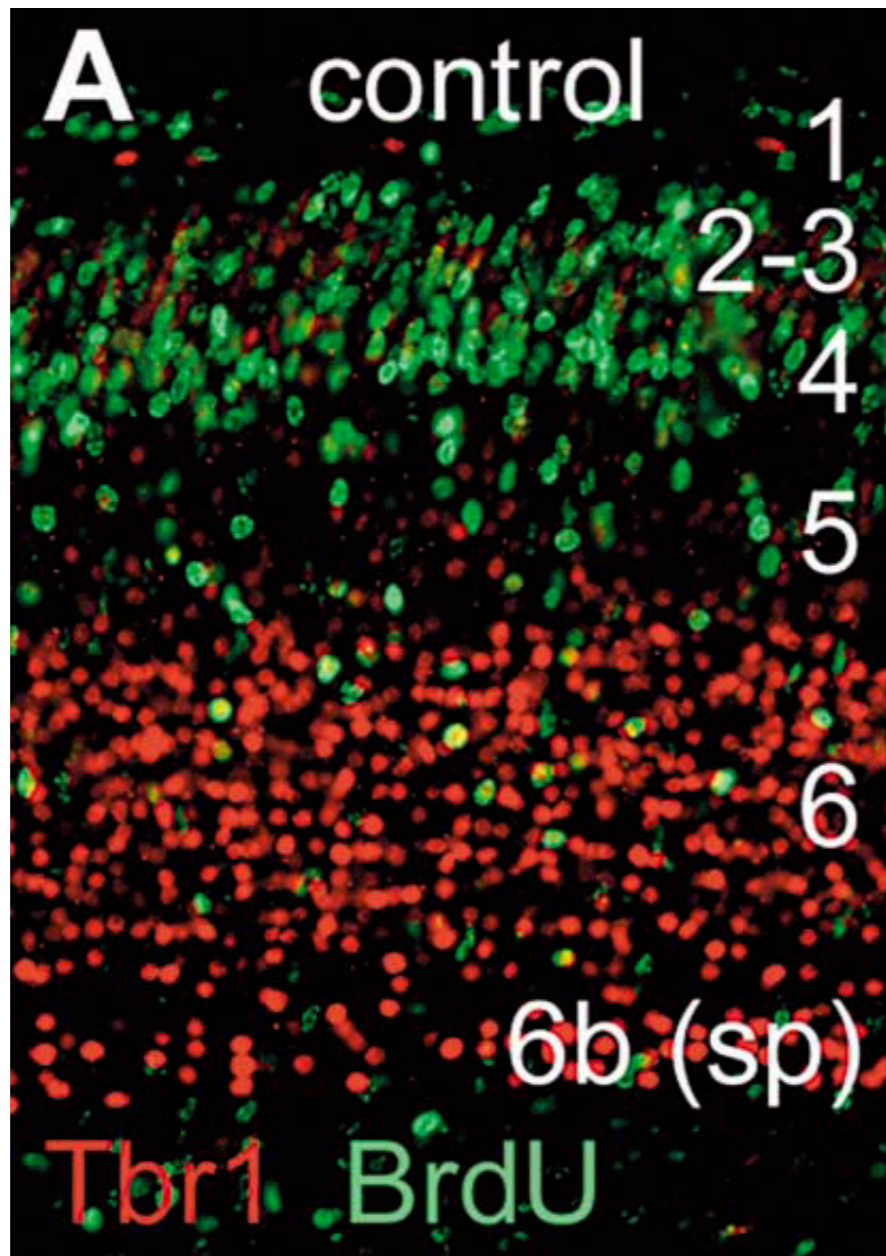
Primate cortex

Rakic, 1987



Hevner et al., 2003

Gene expression patterns can be layer specific



■


Glutamatergic Neurons in Different Layers Have Distinct Connectivity Properties

Layers 2 & 3: Intracortical projections

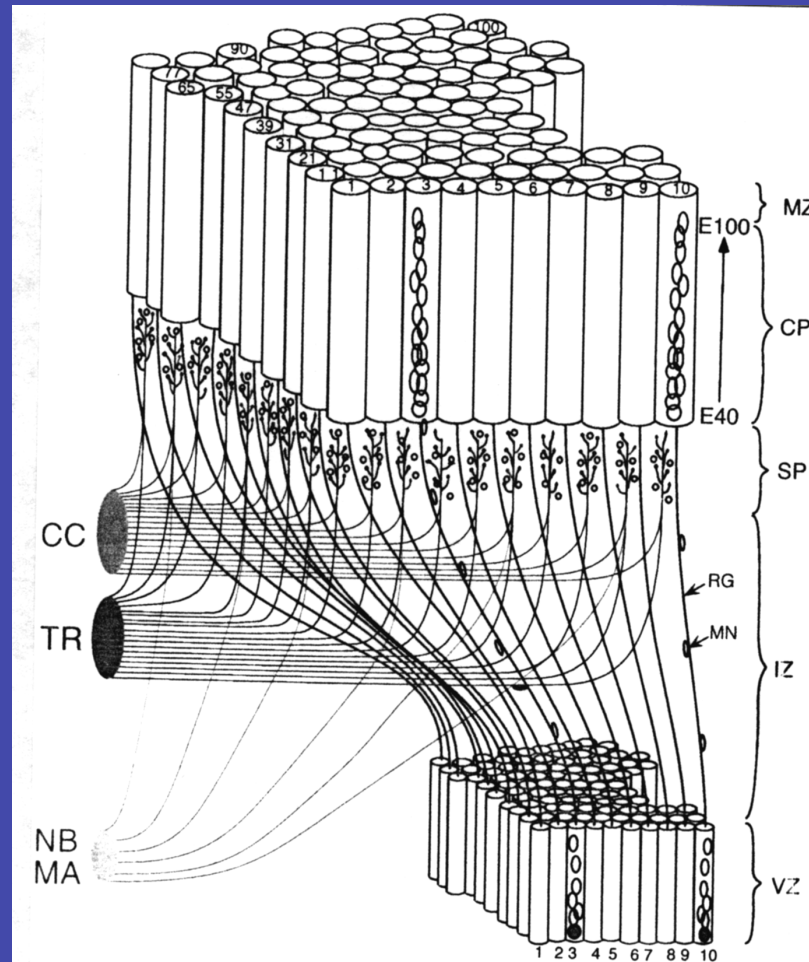
Layer 4: Thalamorecipient

Layer 5: Projects to subcortical areas

Layer 6: Projects to thalamus

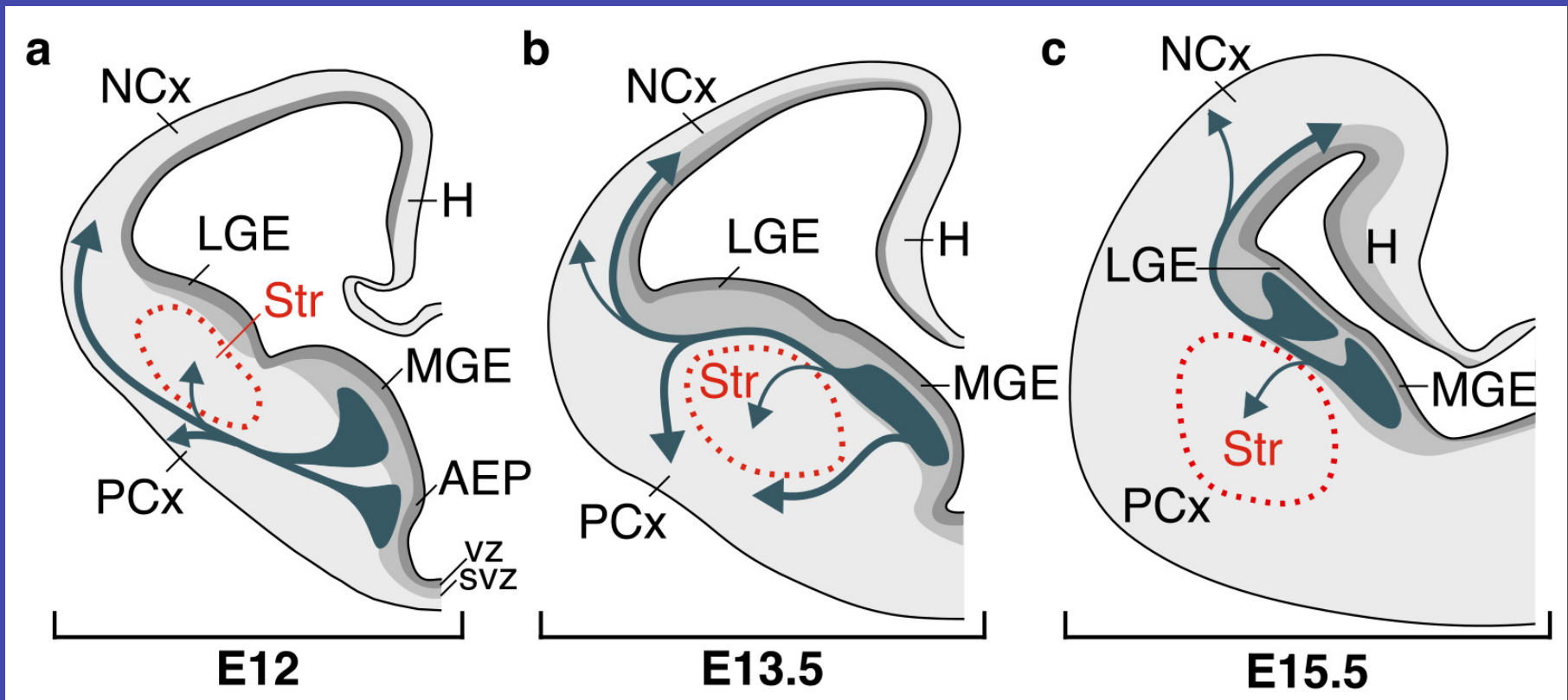


Making the 3rd Dimension: Radial Migration

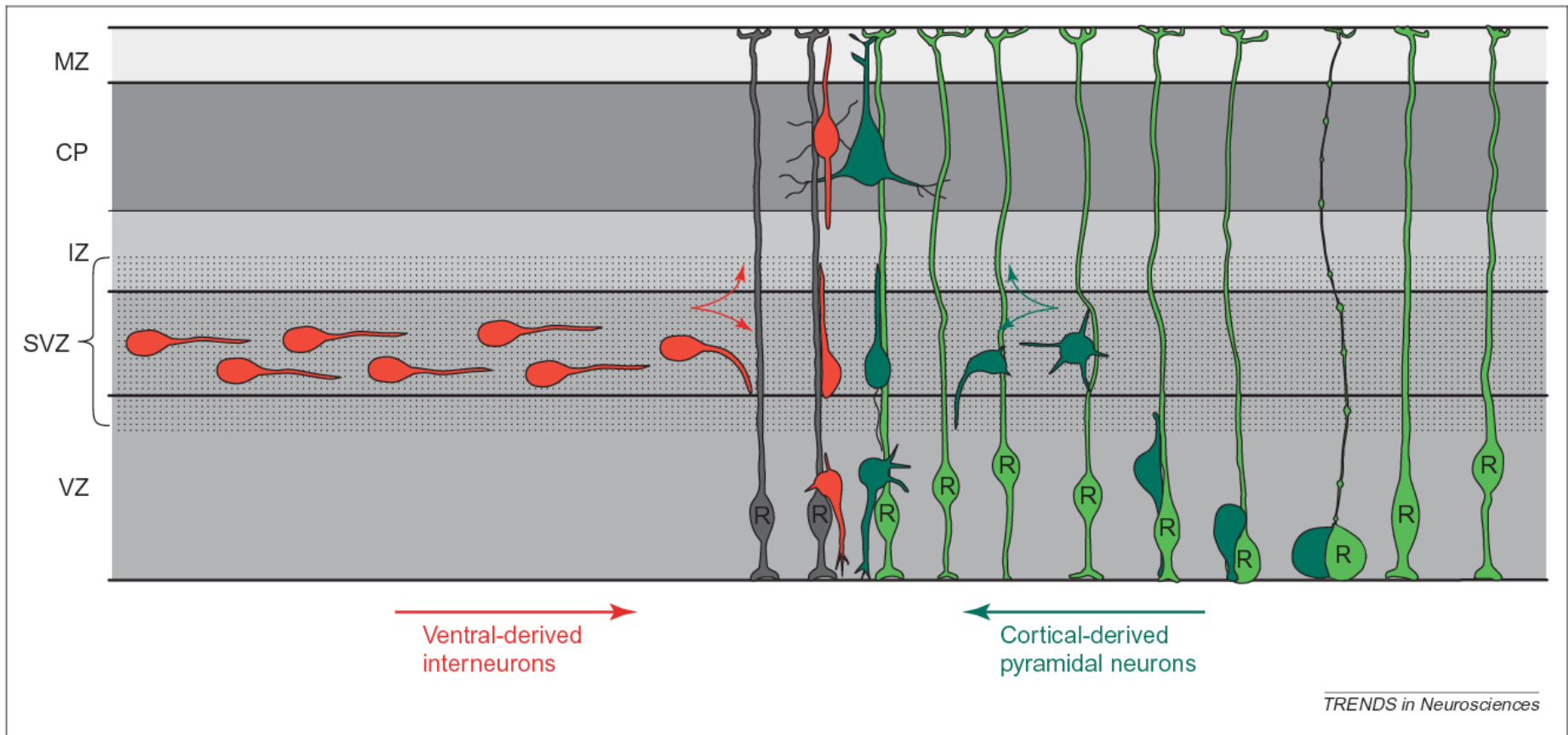


Rakic, 1987

Tangential Migrations from the Basal Telencephalon of GABAergic Interneurons to the Cortex

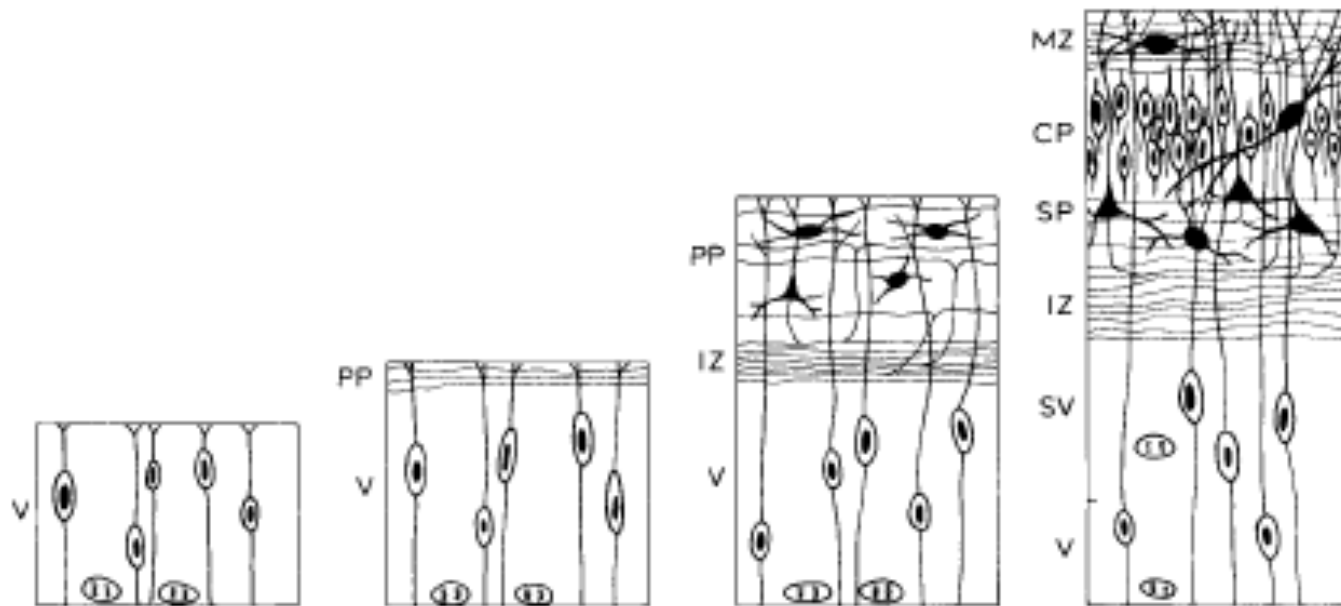


Interactions of Migrating Neurons With Radial Glia



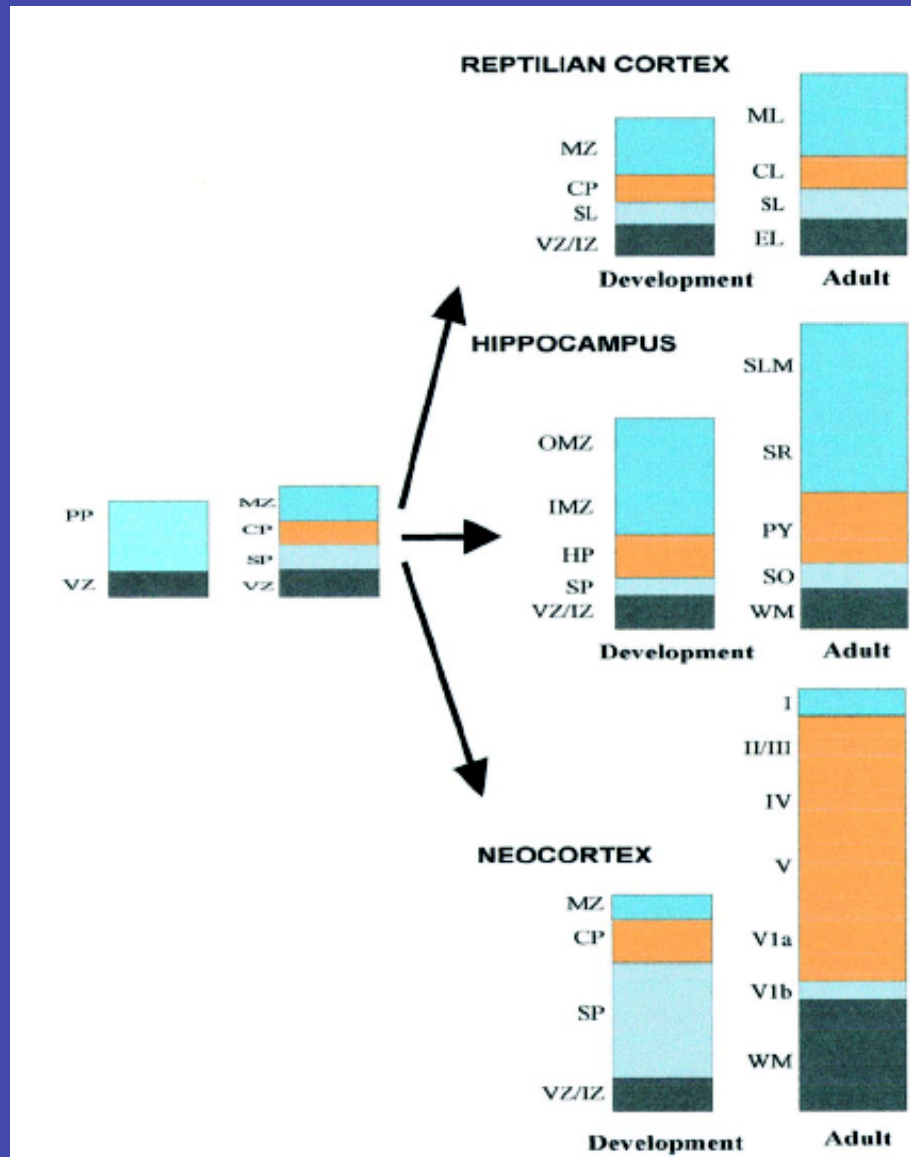
Kriegstein and Noctor, 2004

Early Development of the Cortex: Preplate, Cortical Plate, Marginal Zone and Subplate



Uylings et al., 1990

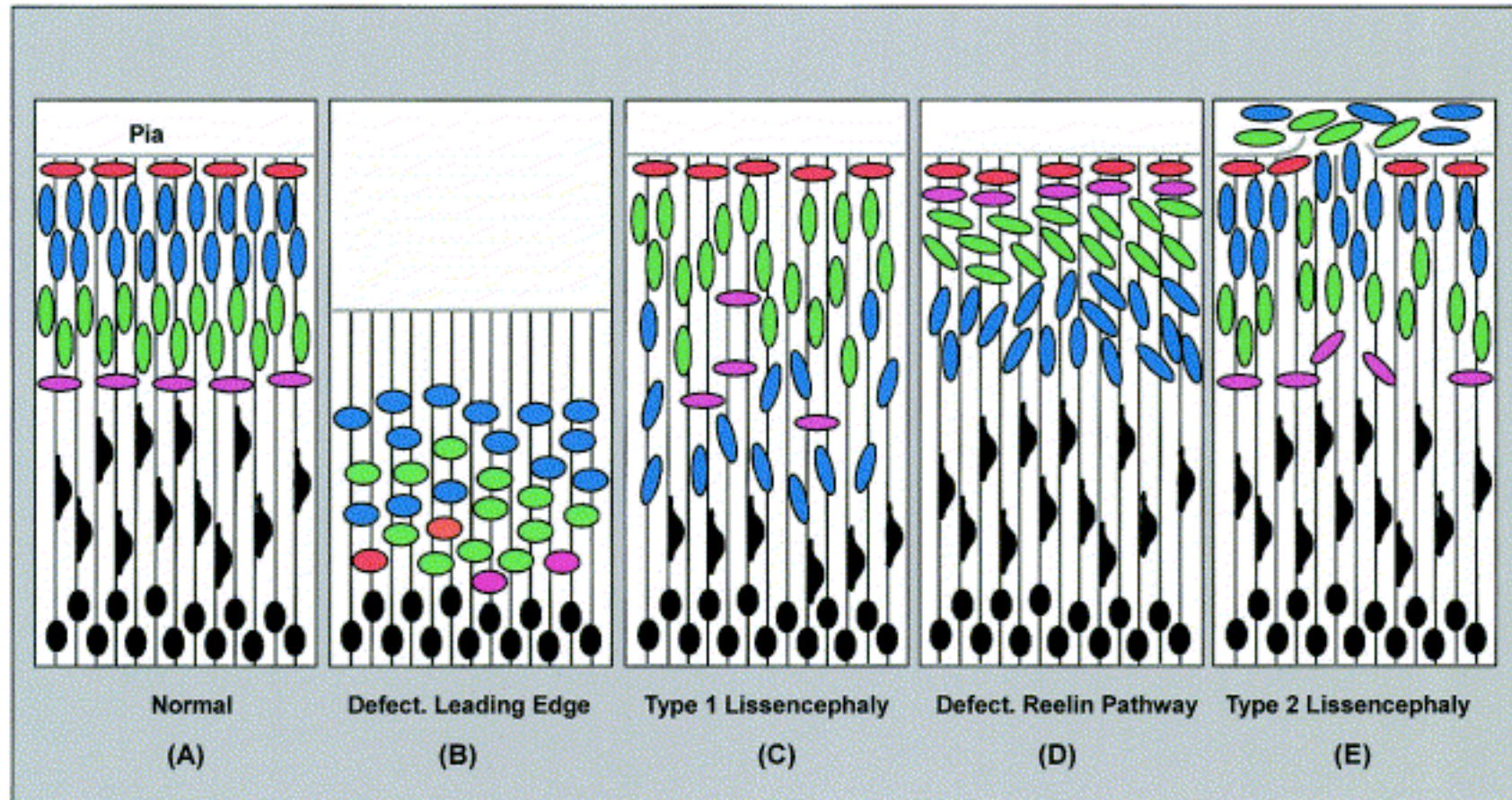
Developmental Organization of Cortical Lamination




“Outside In”

“Inside Out”;
? Role of reelin in
evolution of inside
out cortex.

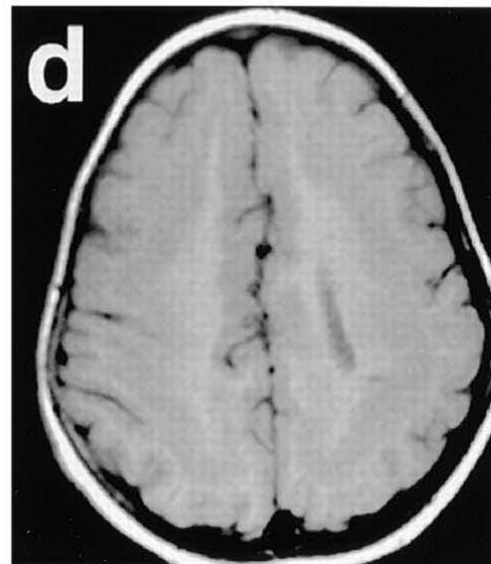
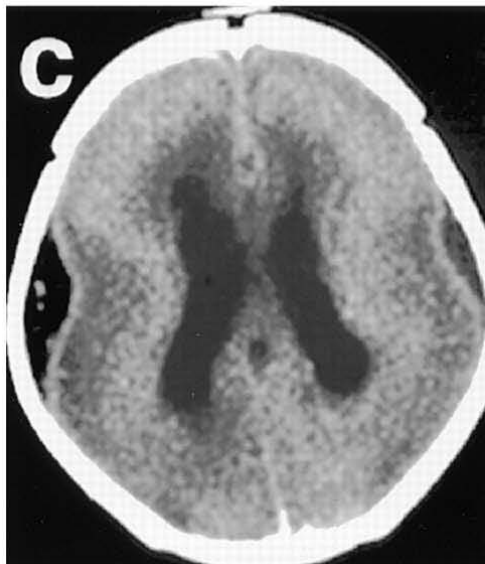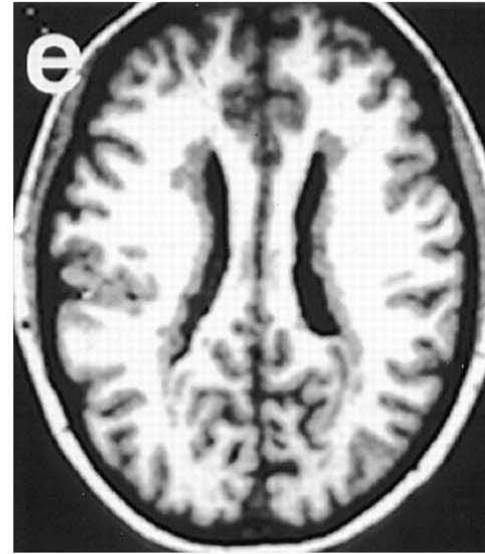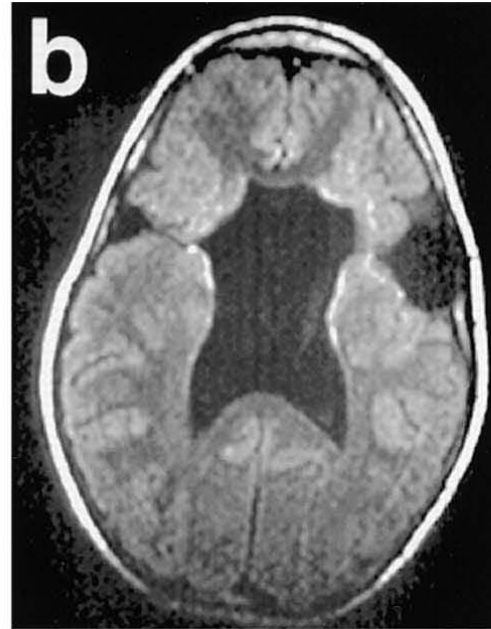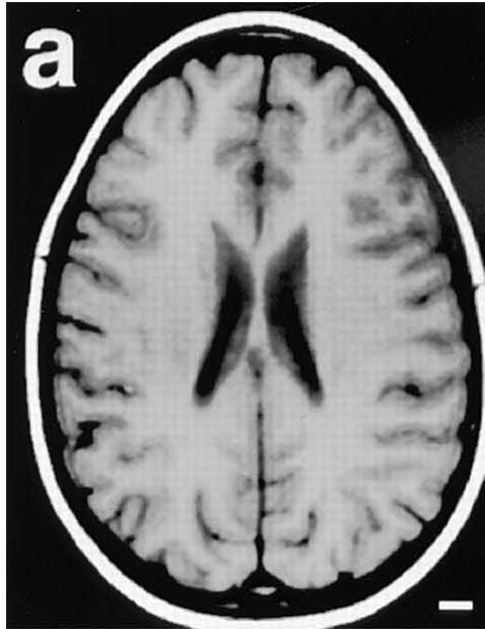
Classes of Mutations that Perturb Cortical Migration



Disorders of radial cortical organization

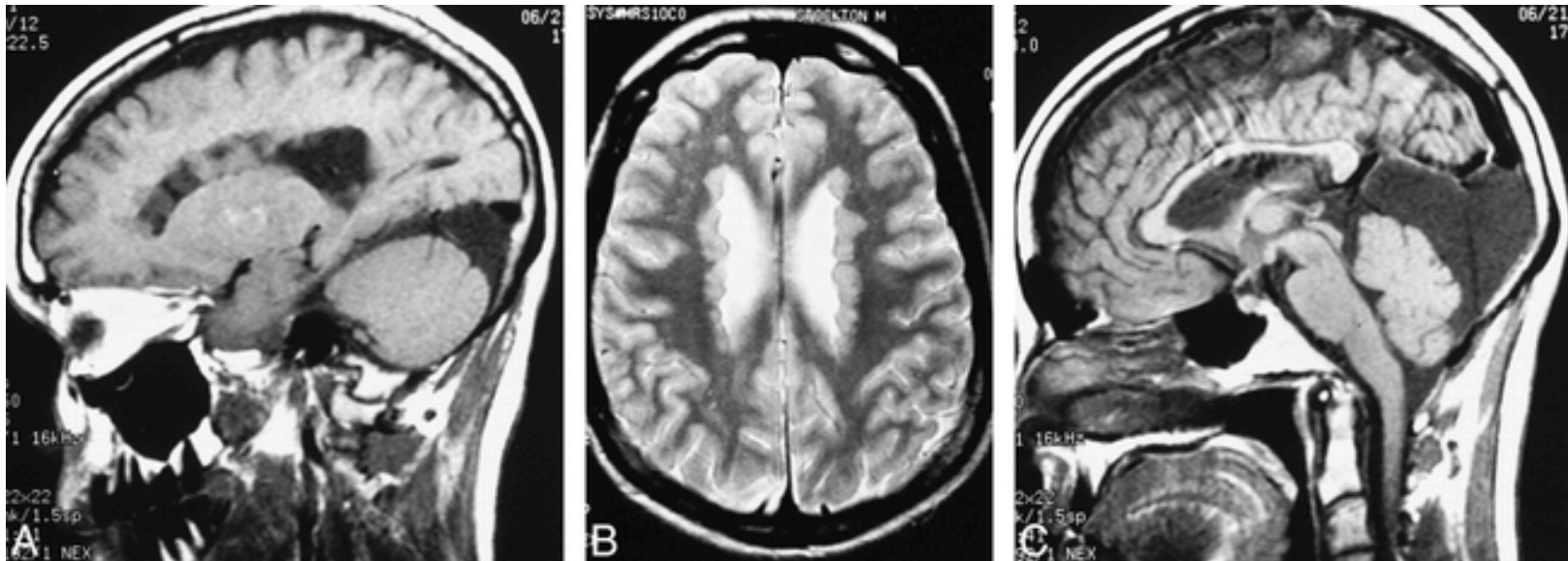


Disorders of neuronal migration in humans

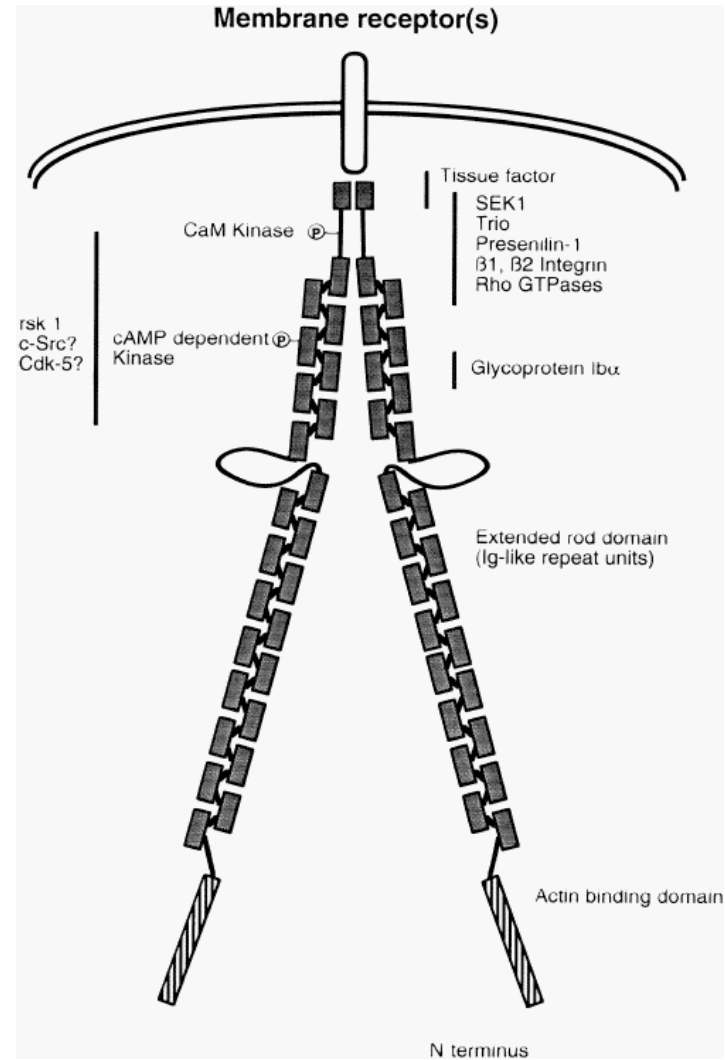
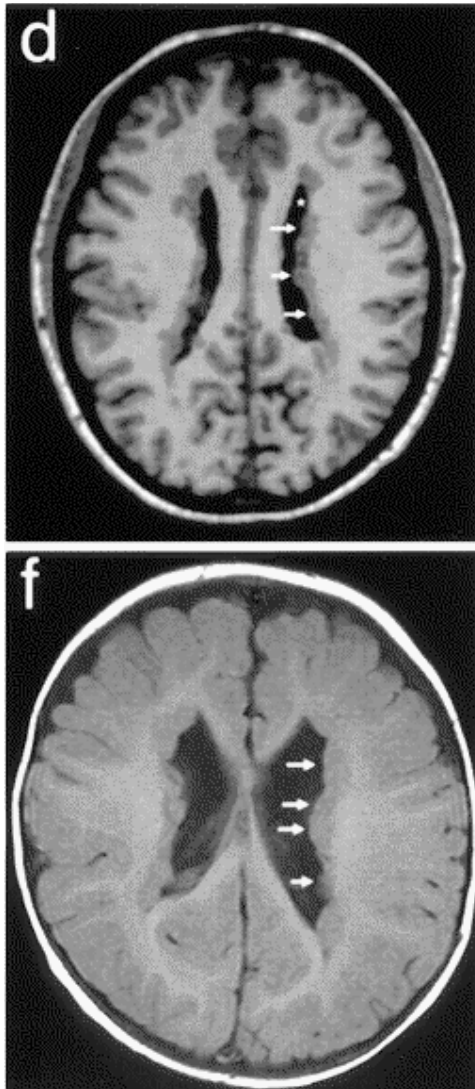


- a. Normal
- b. Schizencephaly
- c. Classic lissencephaly
- d. Double cortex syndrome
- e. Periventricular heterotopia

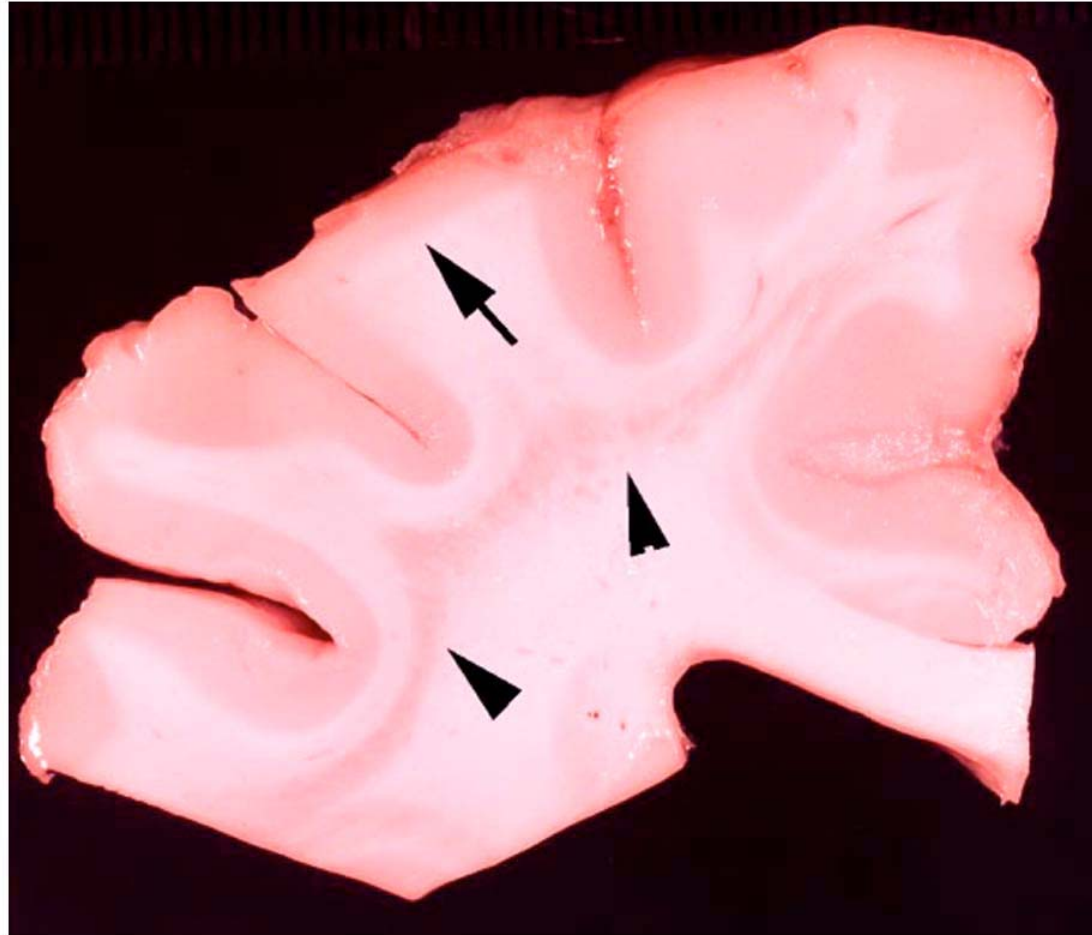
PVNH



Periventricular nodular heterotopia: Mutations in Filamin Prevent Neuronal Migration

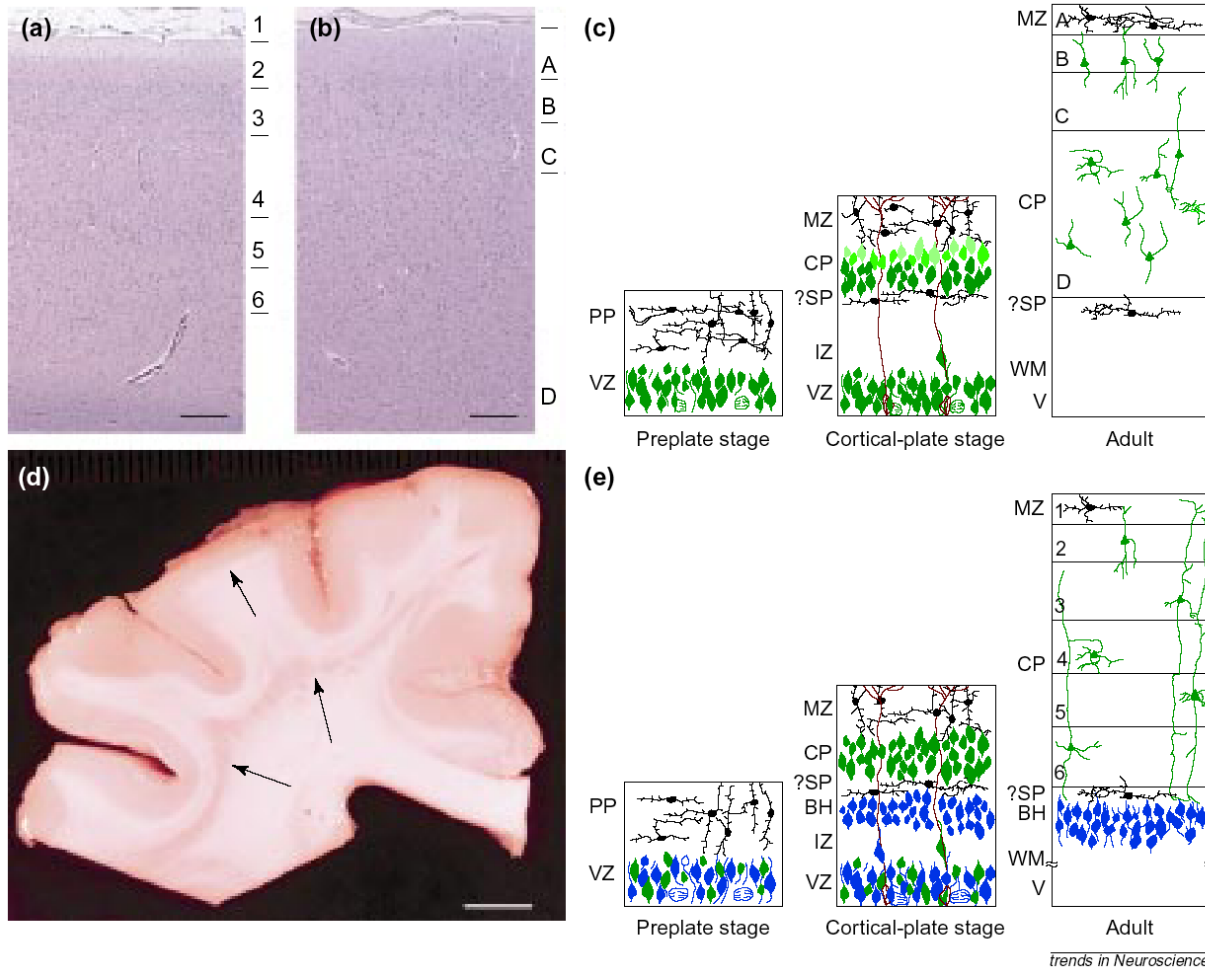


Double cortex syndrome is caused by mutations in a protein named "doublecortin" that binds to microtubules

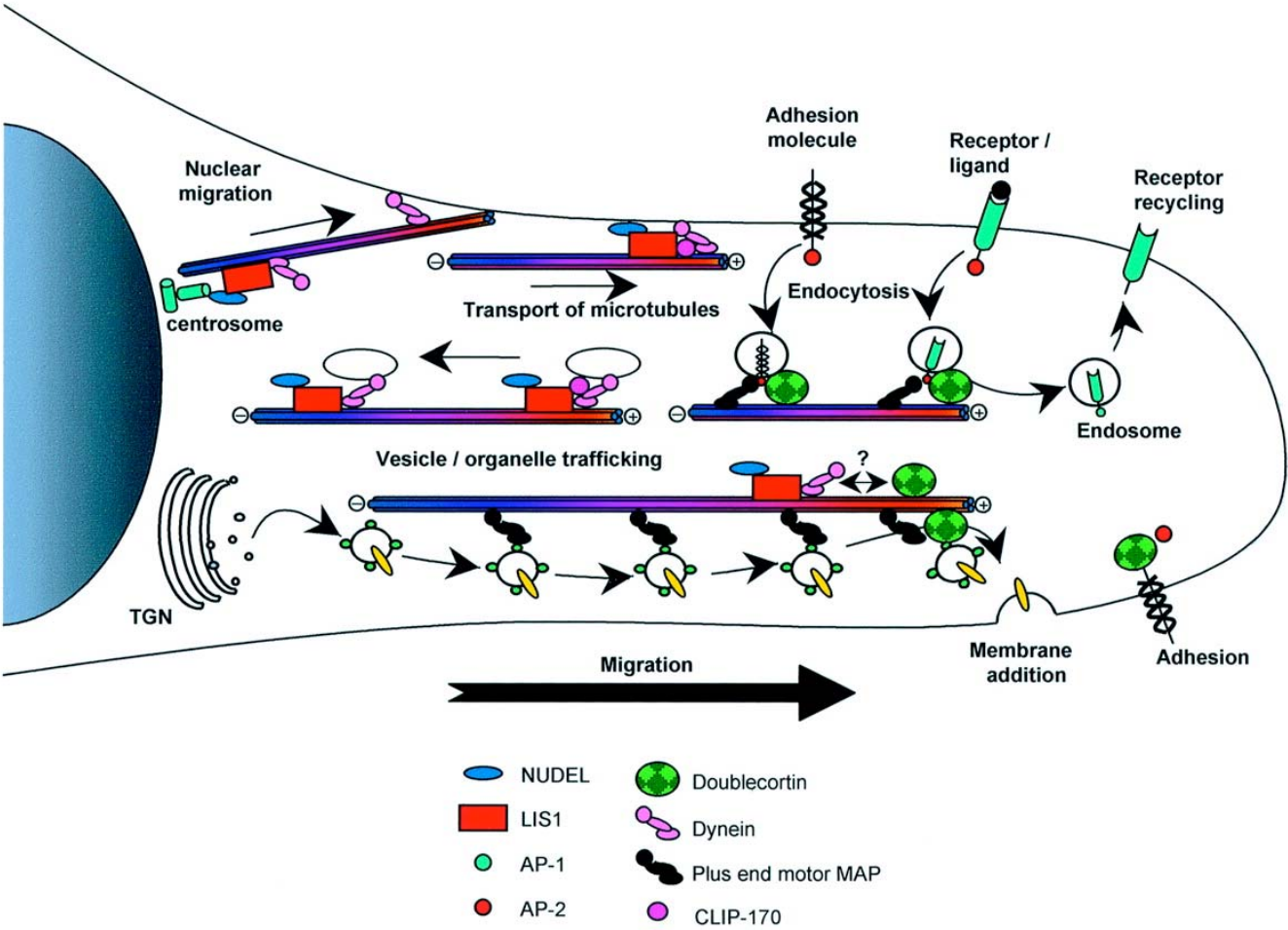


Double cortex syndrome

Subcortical Band Heterotopia - “Double Cortex”

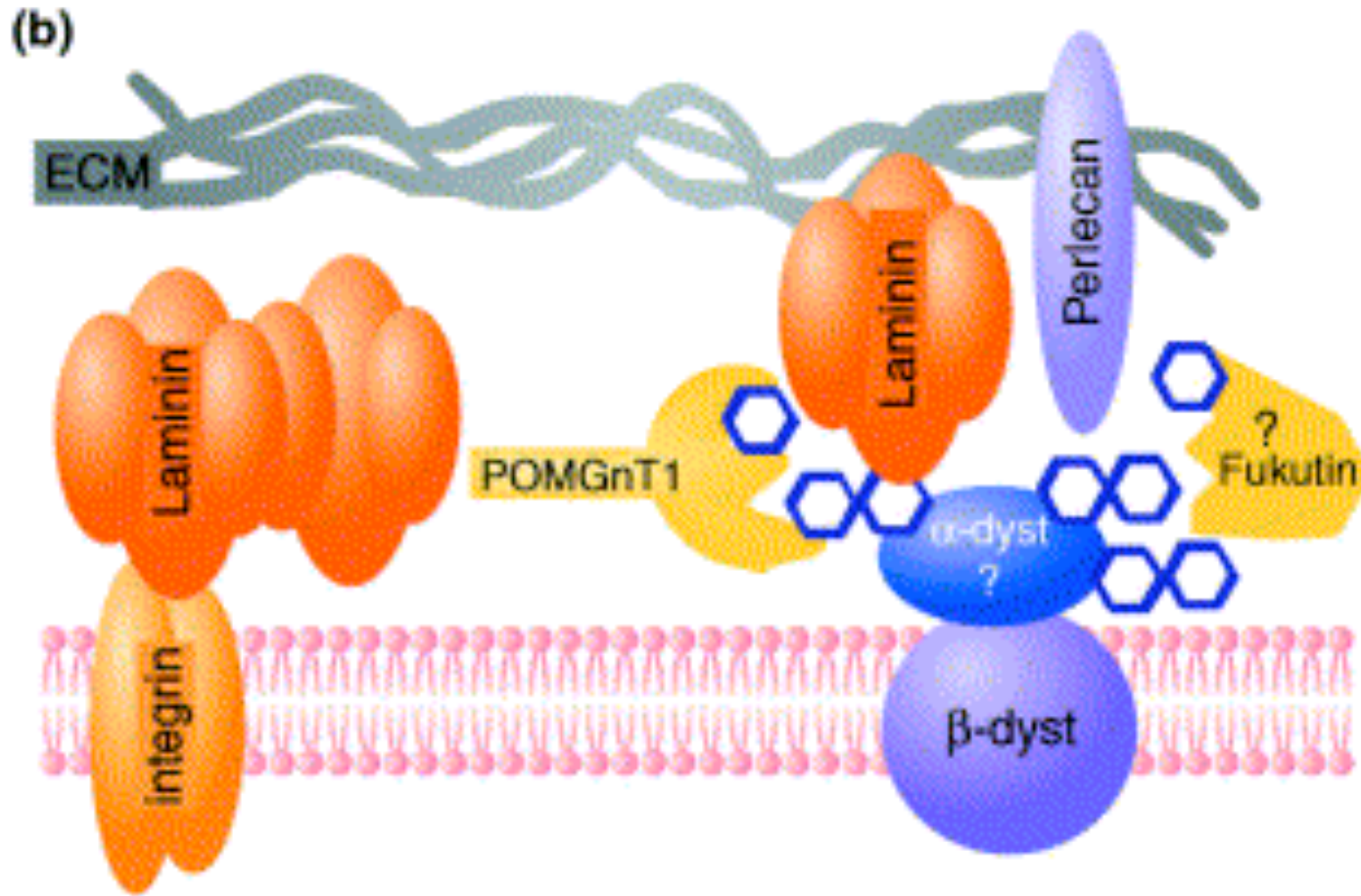


Potential Roles for Lis1 & Doublecortin in migrating neurons

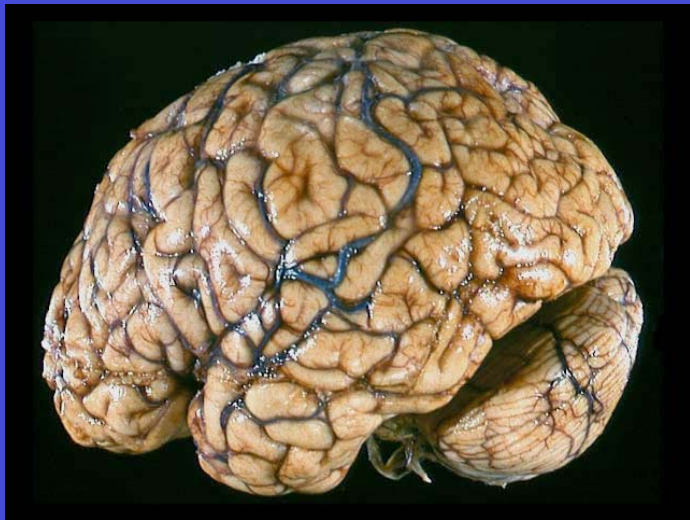

Lis-Nudel-Dynein complex regulates nuclear migration, microtubule transport, vesicle trafficking, membrane addition?

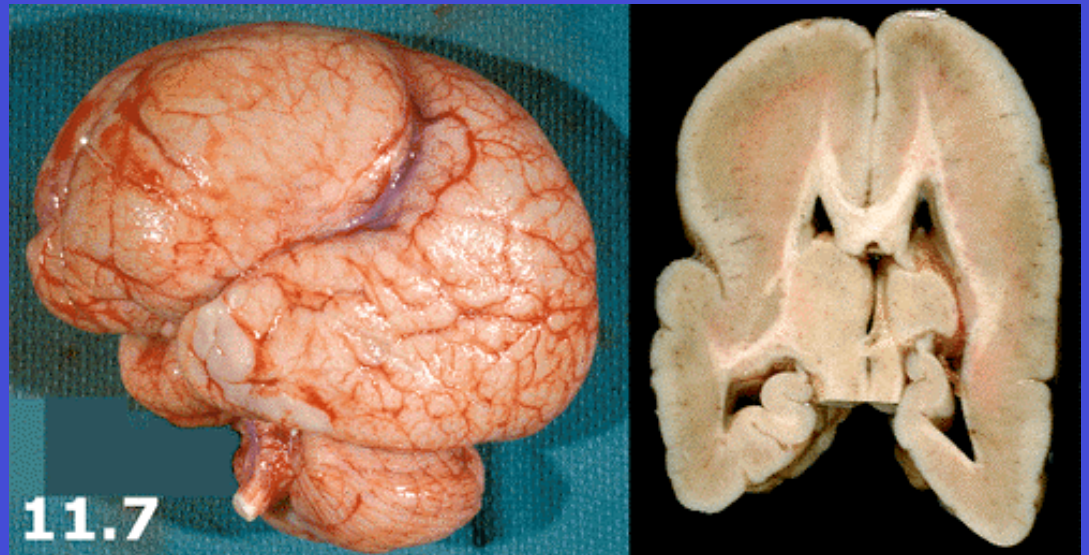
Type II Lissencephaly Gene Products: Regulation of Basal Lamina Assembly



Cobblestone (type II) Lissencephaly

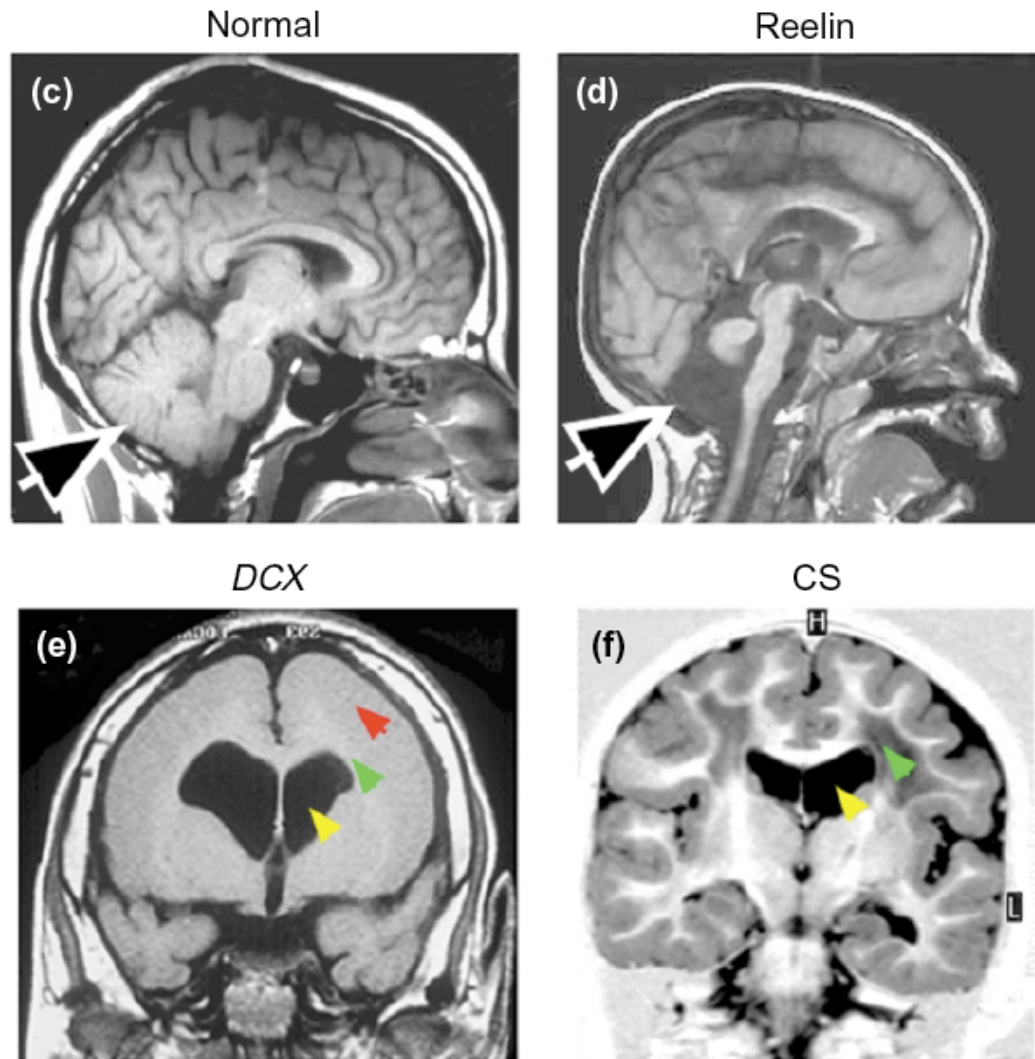


Normal

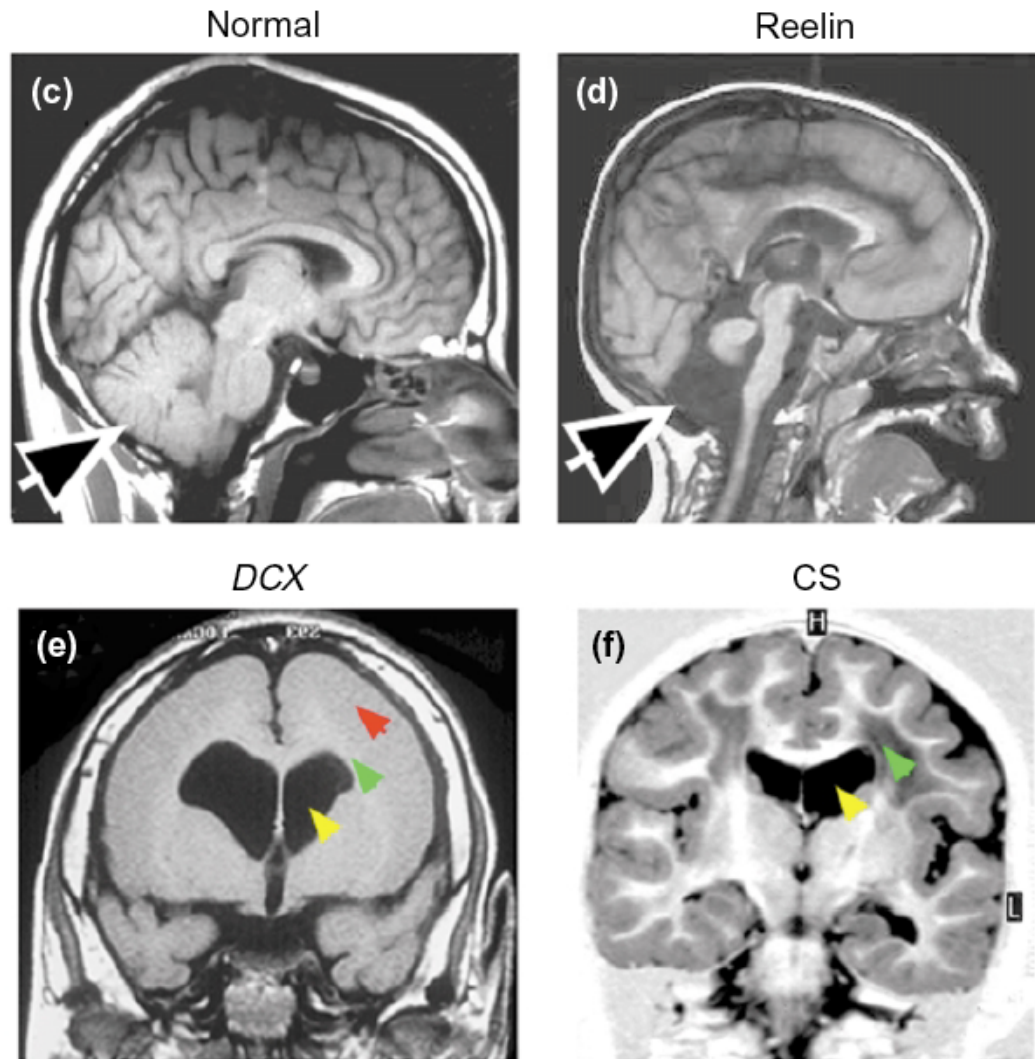


Lissencephaly

Lissencephalies



Lissencephalies



Lissencephalies

